

Received: 2016.11.12
Accepted: 2016.12.01
Published: 2017.06.19

Semivertical Incision: An Aesthetically and Electrophysiologically Effective Mini-Incision Technique for Carpal Tunnel Decompression

Authors' Contribution:
Study Design A
Data Collection B
Statistical Analysis C
Data Interpretation D
Manuscript Preparation E
Literature Search F
Funds Collection G

ABCDEF 1 **Nese Keser**
BCD 2 **Nimet Dortcan**
CDE 3 **Ulas Cikla**
EF 3 **Kutluay Uluc**
CE 1 **Erhan Celikoglu**
BC 1 **Merih Is**
ABD 1 **Bora Gurer**

1 Department of Neurosurgery, Istanbul Fatih Sultan Mehmet Education and Research Hospital, T.R. Health Sciences University, Istanbul, Turkey
2 Department of Electrophysiology Laboratory, Istanbul Fatih Sultan Mehmet Education and Research Hospital, T.R. Health Sciences University, Istanbul, Turkey
3 Department of Neurosurgery, The University of Wisconsin School of Medicine and Public Health, Madison, WI, U.S.A.

Corresponding Author: Nese Keser, e-mail: nkeser@gmail.com
Source of support: Departmental sources

Background: The purpose of this study was to present the clinical results of our retrospective series of carpal tunnel release (CTR) operations. For these operations we used a unique type of incision, for the first time, for treatment of carpal tunnel syndrome (CTS) consisting of a 1-cm semi-vertical (SV) incision made into the wrist crease for macroscopic open CTR.





Material/Methods: This retrospective study included 114 patients (101 females and 13 males) with CTR who were operated upon in our neurosurgery clinic between December 2010 and June 2015. Patient ages ranged from 35 to 83 years (mean 55.05±12.04 years). In total, 127 hands (73 right and 54 left) were operated upon using the SV skin incision technique. After an average follow-up of 18 months (ranging from 6 to 30 months), clinical and electrophysiological (EP) evaluations were performed.

Results: A review of the English language literature published since 1957, when Phalen first popularised the diagnosis and treatment of this disease, determined that no previous reports of the mini-open incision technique as described in our study have been published. In our retrospective patient case review, we found that after operations using the SV incision technique, statistically significant differences were detected in electromyography (EMG) improvements ($p<0.01$). In addition, patients who showed improvement in EMG studies (n=90) were satisfied with the result of their surgery.

Conclusions: Our study demonstrated that 1-cm skin SV incision was a cosmetically satisfying, fast, and safe approach to CTR that was not only clinically effective but also electrophysiologically effective.

MeSH Keywords: **Carpal Tunnel Syndrome • Decompression, Surgical • Electromyography • Patient Satisfaction**

Full-text PDF: <http://www.medscimonit.com/abstract/index/idArt/902343>

 2774  3  5  33



Background

The most common compression neuropathy is carpal tunnel syndrome (CTS) which occurs with compression of the median nerve (MN) in the carpal tunnel. Prevalence of CTS is approximately 1% [1,2], and the main complaint is symptomatic dysesthesia in the distribution area of the digital sensory nerves [3,4]. CTS is three times more common in women than in men, and is usually a disease of middle age with an increased incidence in patients in their late 50s [5,6]. Idiopathic factors are among the most common etiologies [7–9]. The pathophysiology of CTS has been ascribed to mechanical factors: mechanical compression and focal ischemia damage axons which can, in the case of myelinated nerves, be detected with electrophysiological (EP) testing [10]. The “gold standard” of CTS diagnosis is therefore based on both examination findings and EP studies [11,12]. Patients with long-term symptoms unresponsive to medical therapy and those with severe symptoms are selected for surgical treatment [13,14]. Although the literature describes several different methods for surgical treatment of CTS, including open and endoscopic methods [15–21], open surgery is preferable due to the low morbidity rate associated with the procedure [22–25]. Here, we present the clinical results of our retrospective series of carpal tunnel release (CTR) operations, for which a unique type of incision was employed for the first time in CTS—a 1-cm semi-vertical incision (SVI) made into the wrist crease for macroscopic open CTR. The outcome was based on not only cosmetic results and patient satisfaction (PS) but also EP findings.

Material and Methods

The present retrospective review included 114 patients (101 females and 13 males) operated upon between December 2010 and June 2016 by the same neurosurgeon (KN). Patient ages ranged from 35 to 83 years (mean 55.05 ± 12.04 years). In total, 127 hands (73 right and 54 left) were operated upon with the SV skin incision technique. After an average of 18 months follow-up (range from 6 to 30 months), clinical and EP evaluations were performed. Pre-diagnosis of CTS was based on one or more of the following symptoms: hand pain, muscle weakness, paresthesia and hypoesthesia in the MN distribution, thenar muscle atrophy, and positive Tinel’s sign and Phalen’s maneuver. Primary complaints of pain and numbness in the hand causing arousal from sleep were reported for 114 hands (87.5%), and strength loss was reported for 34 hands (26.8%). Phalen’s maneuver was positive in 108 hands (85.4%), Tinel’s sign was positive in 93 hands (73.2%), and hypoesthesia occurred in 82 hands (64.5%). Thenar atrophy was found in 27 hands (20.8%) and opposition weakness in 12 hands (10.4%). Of the 114 patients, 37 (33.3%) had diabetes mellitus (DM), 14 (11.9%) had hypothyroidism (HT-H), 3 (2.3%) had chronic

renal failure (CRF), and 3 (2.3%) had rheumatoid arthritis (RA). The polyneuropathy (PNP) rate was 11.2% (12 of 114 patients).

We evaluated patient satisfaction using the Patient Satisfaction Survey (PSS), as described by Macey and Burke in 1995, which is a 5-point questionnaire with the following response metrics: “full, 5 points; “quite, 4 points; “moderate” 3 points; “less”, 2 points; “no” 0 points.

For the EP evaluation, the definitive diagnosis of CTS was made by electromyography (EMG). Patients who did not show signs of recovery after at least three months of medical treatment, and patients with moderate or severe CTS symptoms according to the American Association of Electrodiagnostic Medicine (AAEM), were included in the study. Only individuals known to have had a traumatic injury to the MN, and pregnant women were excluded.

Preoperative (PreOP) EMG studies were performed in the final month of the Preop term, and postoperative (Postop) studies were performed on average 12 months (range 6 to 18 months) into the Postop period by the same neurologist (DN) at the same hospital. The nerve conduction examination was performed while the patient was in a comfortable supine position at room temperature, with a skin temperature of 32–33°C. Median and ulnar sensory conduction studies were performed Preop and Postop. The EP study results were classified according to the AAEM guidelines, regarding the degree of MN lesion.

The AAEM classification, as described previously [26]: (1) mild CTS: only sensory interaction of the M’s wrist segment; prolonged median sensory peak latency and falling sensory amplitude; (2) moderate CTS: abnormal median sensory interaction with the addition of motor distal latency prolongation; (3) severe CTS: median motor and sensory distal latency prolongation in addition to sensory and motor amplitude decrease; (4) very severe CTS: median sensory or motor responses cannot be measured.

In the sensory and motor nerve conduction studies, surface electrodes were used for recording and alerts (bars for motor recording, ring electrodes for sensory recording).

Sensory conduction studies were performed by the orthodromic method. Inputs were given at the second digit with a ring electrode and recorded approximately 12–14 cm proximal to the wrist. For motor examination, the recording electrode was placed on the thenar area by locating bar electrodes on the abductor pollicis brevis muscle approximately 7 cm proximal to the wrist.

The following were used as nerve conduction parameters: (1) median sensory conduction velocity (SCV) in meters per second (m/s); (2) median peak distal sensory latency (DSL) in milliseconds (ms); (3) median sensory nerve action potential

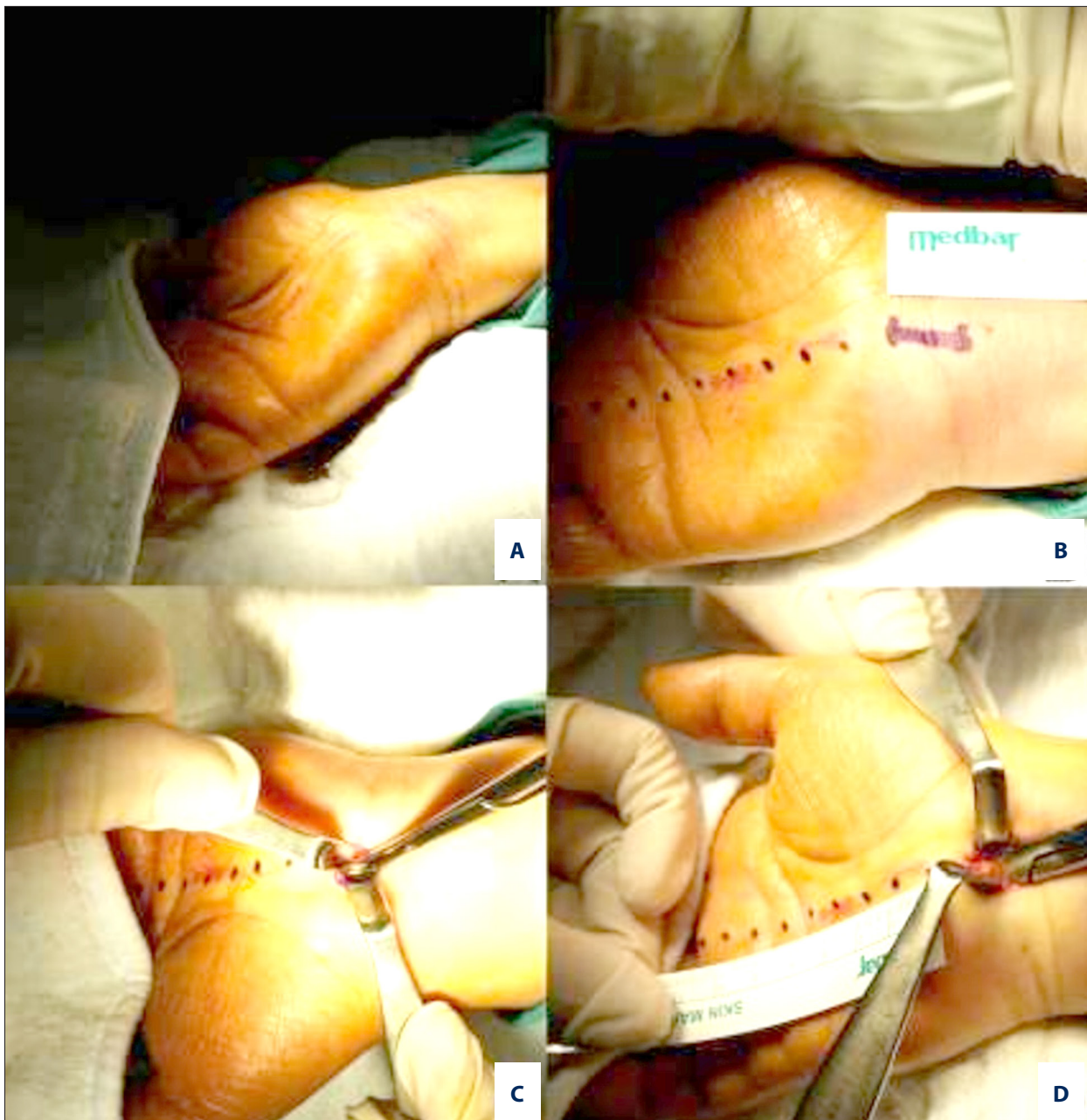


Figure 1. (A) Hand position; (B) location of the incision line; (C) scissor tip is under the ligament; (D) ligament was opened up to the endpoint.

amplitude (SNAPa) in millivolts (mV); (4) median distal motor latency (DML) in (ms); and (5) median motor compound muscle action potential amplitude (CMAPa) in(mV).

The following were considered normal and pathological values: (1) SCV: normal 52 m/s, pathological 42 m/s; (2) DSL: normal 2.8 ms, pathological 3.4 ms and above; (3) SNAPa: normal 15 mV, pathological 8 mV and below; (4) DML: normal 3.4 ms, pathological 4.0 ms and above; and (5) CMAPa: normal 8 mV, pathological 4 mV and below.

Surgical technique had the patients in a supine position on the operating table. The arm of the affected hand was placed on an arm board in an abducted position with the forearm supinated. A gauze compress was placed beneath the distal forearm, and the wrist was slightly extended to improve visibility (Figure 1A). The site for the incision was marked at the wrist crease with a line drawn perpendicular to the medial axis of the third finger (Figure 1B). The surgery was carried out under local anaesthesia and without microscopic magnification, tourniquet, or bipolar cautery. A 1-cm long SV skin incision was

Table 1. The effects of various variables (age, sex, additional diseases and improvement in the EMG) on the PSS.

		Patient satisfaction survey (PSS)		<i>p</i> ^a
		Negative	Positive	
		Mean ±SD (median)	Mean ±SD (median)	
Age (year)		53.67±15.98 (49.5)	55.28±11.53 (55.0)	0.529
		n (%)	n (%)	<i>p</i> ^b
Sex	Man	2 (%11.7)	11 (%11.3)	1.000
	Woman	15 (%88.3)	86 (%88.7)	
Additional diseases	Yes	3 (%18.7)	43 (%44.3)	0.647
	No	14 (%87.5)	55 (%55.7)	
Improvement in the EMG	No	13 (%43.3)	17 (%56.6)	0.001**
	Yes	0 (%0)	97 (%100)	

^a Mann Whitney U Test; ^b Fisher’s Exact Test; ** *p*<0.01.

made, and the subcutaneous adipose tissue was retracted bilaterally with mini hand retractors. After exposing the transverse carpal ligament (TCL), it was opened with a No. 15 scalpel above the MN.

The tip of the dissection scissors was placed under the TCL from this opening, and the ligament was raised slightly to protect the MN (Figure 1C). The TCL was then opened by gently and slowly advancing the scissors until the end of the ligament could be felt distally (Figure 1D). The proximal section of the TCL was opened in the same fashion. (Minor bleeding may occur during the dissection, but this can be easily controlled by direct compression for approximately two minutes.) The incision made in the TCL was located closer to the ulnar side of the MN to decrease the risk of injury to the palmar cutaneous and recurrent motor branches. After attaining hemostasis, the skin was closed with interrupted 3.0 Vicryl sutures without subcutaneous sutures and wrapped with an elastic bandage. The mean operative time was 10 minutes, ranging from 5 to 15 minutes. A single dose of second-generation cephalosporin was administered PreOP.

Patients were instructed to avoid wrist movements, but not those of the arm or fingers, until Postop day 15.

Statistics

NCSS (Number Cruncher Statistical System) 2007 (NCSS, Utah, USA) and PASS (Power Analysis and Sample Size) 2008 (NCSS, Utah, USA) software were used for statistical analysis of Preop and Postop EMG results of 114 patients (127 hands). Evaluation of the data included descriptive statistical methods (mean, standard deviation, median, frequency, rate, minimum, and maximum) and in the case of normally distributed quantitative data, the Mann-Whitney U-test was used for statistical

comparison. The Fisher’s exact test was used for a qualitative comparison of data. The Wilcoxon signed-rank test was used for Preop and Postop assessment analyses. Statistical significance was defined as *p*<0.01 or *p*<0.05.

Results

Statistically significant differences were detected in EMG improvements (*p*<0.01) (Table 1). Patients showing improvement in EMG studies (n=90) were satisfied with the result of the surgery. Of those who experienced no such EMG improvements (n=37), 21 patients were satisfied with the result of the surgery. None of the patients in this study suffered from complications such as injury to the MN or its branches, sympathetic dystrophy, hematoma, or deep infection. Superficial wound infection was observed in four patients; these patients were successfully treated with antibiotic therapy. The mean time taken before patients returned to their daily routine jobs was 15 days and ranged from 10 to 20 days. Wound tenderness was reported in 25% of cases, and improved within an average of three months. In none of the patients did painful hypertrophic scar formation occur in the Postop period (Figure 2). Patient satisfaction did not differ significantly by patient age, sex, or comorbidity (*p*>0.05). In almost all cases there were complaints of night-waking pain and numbness during sleep in the Preop period, which disappeared in the Postop period, showing that this was the most important factor in the patient satisfaction.

Electrophysiological evaluation

According to the AAEM guidelines, Preop and Postop EMG results are shown in Table 2 and Figure 2. Preop EMG grading ranged between 2 and 4, with a mean of 2.85±0.62 and a median of 3. Postop EMG grading ranged from 0 to 4 with a mean

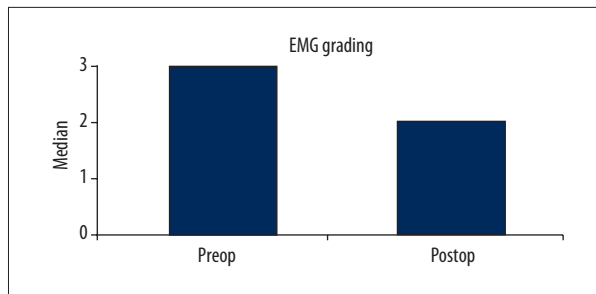


Figure 2. There is statistically significant improvement between Preop and Postop EMG grading according to the AAEM guidelines.

of 1.98 ± 0.91 and a median of 2. An average improvement in EMG grading of 0.87 ± 0.76 between Preop and Postop evaluations was found to be statistically significant ($p=0.001$, $p<0.01$) (Table 2). The Postop EP comparison of 127 hands for which we

obtained detailed Preop EMG evaluations is shown in Table 3 and Figure 3. An average decrease in median DML, occurring between Preop and Postop measurements, of 1.41 ± 2.15 was found to be significant ($p=0.001$, $p<0.01$), as was the average increase of 1.28 ± 3.67 mV in Postop CMAPa ($p=0.011$; $p<0.05$), average decrease of 0.57 ± 0.53 in median DSL ($p=0.001$; $p<0.01$), average increase of 5.02 ± 4.78 mV in median SNAPa ($p=0.001$, $p<0.01$), and average increase of 12.60 ± 17.93 m/s in the median SCV measurement ($p=0.001$, $p<0.01$) (Table 3).

Discussion

Despite its high success rate and “gold standard” status, CTR open surgery with long palmar incision carries the risk of injury to the palmar cutaneous and recurrent motor branches of the MN. This traditional approach also carries the risk of pillar pain and painful

Table 2. Preoperative and postoperative EMG gradings.

		Preop n (%)		Postop n (%)	
EMG grading	0	0	(%0)	6	(%4.7)
	1	0	(%0)	32	(%25.2)
	2	34	(%26.8)	55	(%43.4)
	3	77	(%60.6)	29	(%22.8)
	4	16	(%12.6)	5	(%3.9)
	Min–Max (median)	2–4 (3)		0–4 (2)	
Ort \pm SD	2.85 \pm 0.62		1.98 \pm 0.91		
p		0.001*			

Wilcoxon Ranks Test * $p<0.01$.

Table 3. Preoperative and postoperative latency, amplitude and velocities.

n=40		Preop	Postop	p
Median Distal Motor Latency (DML)	Min–Max (median)	1–14 (5.2)	3–8 (4.2)	0.001**
	Mean \pm SD	5.87 \pm 2.42	4.49 \pm 1.09	
Median motor Compound Muscle Action Potential amplitude (CMAPa)	Min–Max (median)	0–14.5 (6.0)	0.4–12.9 (8.2)	0.011*
	Mean \pm SD	6.12 \pm 4.17	7.40 \pm 3.21	
Median peak Distal Sensory Latency (DSL)	Min–Max (median)	3.2–5.1 (3.8)	2.8–4.5 (3.4)	0.001**
	Mean \pm SD	3.98 \pm 0.51	3.50 \pm 0.42	
Median Sensory Nerve Action Potential amplitude (SNAPa)	Min–Max (median)	0–14 (4.8)	0–18 (9.9)	0.001**
	Mean \pm SD	4.70 \pm 4.33	9.72 \pm 4.78	
Median Sensory Conduction Velocity (SCV)	Min–Max (median)	0–38 (29.3)	0–50 (37.0)	0.001**
	Mean \pm SD	21.19 \pm 15.97	33.80 \pm 13.16	

Wilcoxon Ranks Test ** $p<0.01$; * $p<0.05$.

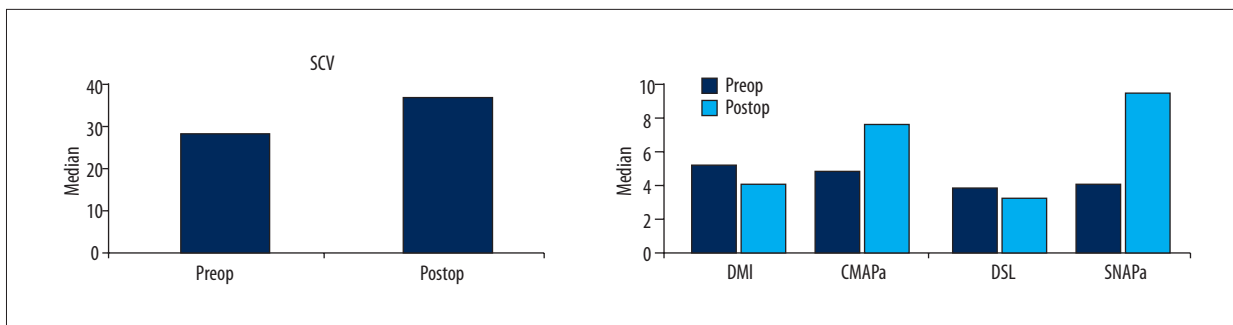


Figure 3. There is statistically significant decrease in motor and sensory latency in Postop versus Preop period, and there is statistically significant increase in motor and sensory amplitude in Postop period compared to Preop period.

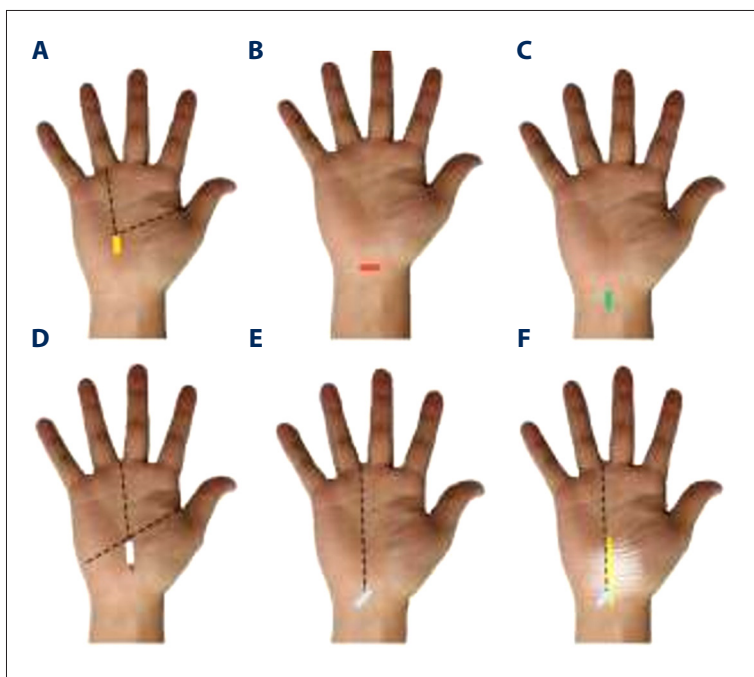


Figure 4. (A) Avci incision; (B) Cellocco incision; (C) Isik incision; (D) Serra incision; (E) SV incision; (F) SV incision, ligament and nerve.

hypertrophic scar formation. These risks led us to explore different types of the incision with which to perform the open surgery (Figure 4A–4D) [15,17,18,20]. For example, a small palmar incision has been used to overcome these complications (Figure 4D) [11,20], and its use achieved good clinical results, but the risk of injury to the MN cannot be ignored. Lee et al. [19] reported MN injury in two cases within a series of 525 patients (694 hands).

There are no previous reports of the mini-open incision described in our study in the English-language literature (Figure 4E, 4F). SV incision enables quick release of the TCL by avoiding the subcutaneous adipose tissue, and provides excellent visibility, eliminating the need for an operating microscope. The proximal portion of the ligament can be opened easily as the incision site is in the wrist fold. In our case series, there were no complications such as injury to the MN or its branches, pillar pain, or painful scar formation. Although we did not use a tourniquet or bipolar coagulation, we observed

no palmar hematoma. Additionally, the cosmetic results of SV incision were excellent (Figure 5).

The PSS has many advantages for clinical evaluation, such as ease of understanding and speed of interpretation. Furthermore, Dias et al. [27] reported that the PSS is a reliable survey.

Typically, idiopathic CTS patients have been included in studies of CTR in the literature. Even though comorbidities were not a selection criterion in our series, our patients experienced significant symptomatic relief. Of our 114 patients, 57 (50%) had comorbidities, including DM, HT-H, CRF, and RA, and 12 patients (11.2%) had PNP. On the PSS, 87.6% of the patients had complete relief, 8.5% had partial relief, and 3.9% had no relief from their symptoms.

In spite of ongoing discussions as to whether EP studies ought to be conducted in the diagnosis of CTS, we stand by our use

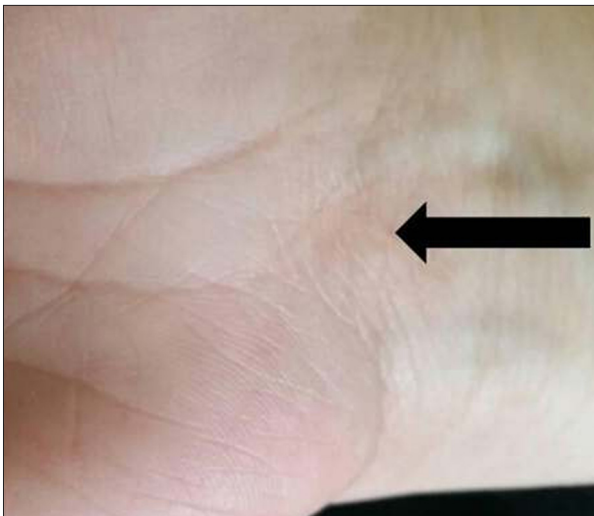


Figure 5. SV 1-cm skin incision appearance (arrow) after an operation performed 12 months previously.

of EP variables, as they ensure an objective means by which to assess nerve compression.

Because it is difficult to evaluate subjective symptoms and physical findings after CTR, the only way to determine and quantitate improvement after decompression is by objective nerve conduction studies. This evaluation is of utmost importance in patients who claim no clinical improvement after surgery or whose symptoms recur a while after decompression.

Despite certain published reports that concluded that the success of the CTR was not correlated with EP findings [28,29], other studies indicated a moderate correlation between neurophysiological and clinical results [30].

Some studies published in recent years highlighted improvements in the results of neurophysiological examinations in the Postop period. Ginanneschi et al. [31] reported improvements in all EMG parameters measured at six months into the Postop period; this study suffered, however, from a limited sample size.

In a larger study by Prick et al. [32], remission was observed in the form of reduced MN sensory response and motor latency was measured in the EMG studies performed six and 12 months after CTR, though these parameters did not return to the normal range of values.

El-Hajj et al. [33] detected 82.3% improvement in EMG parameters in their study of 24 hands (18 patients) and this ratio rose to 88.2% in the nine Postop months. Only 47% (8 patients), however, were partially satisfied or completely satisfied with the results. The remaining patients continued to complain of serious symptoms, despite having improved or normal nerve conduction. In the same study, significant improvements were

observed in the median DML, DSL, and SCV six months after the Postop term.

Similar to the El Hajj et al. [33], although the clinical and EP results did not overlap exactly, Postop EMG improvements in our study were found to be statistically significant (Table 3, Figure 3). In our study, EMG signs of CTS totally disappeared in 4.2% of cases, and EMG improvement was observed in 68.7% of cases after an average of 12 months (Table 2, Figure 2).

While the preoperative median sensory response (MSR) was absent in 42% (53) of hands, after the surgery this ratio fell to just 14% (18). This finding indicates that median sensory response was restored in 65% of patients in whom this response was originally absent.

Similarly, although median motor responses could not be elicited in 10% (13 hands) PreOP, only in 2% (3 hands) could it not be achieved Postop. The return of lost EP responses was therefore quite significant in our present study.

Our findings may, therefore, be compared to those of El-Hajj et al. [33]; however, the patient selection criteria employed by El-Hajj et al., and in other previous studies, were rather exclusive, particularly with respect to patients with comorbidities. In our study, the patient group was very heterogeneous and the patients with DM, CRF, RA, PNP, and HT-H were included. Our findings of success with the SV incision technique may, therefore, be said to possess great external validity.

Furthermore, we included in our study patients with intermediate and advanced CTS findings as determined by EMG, and therefore can be confident that the procedure was effective in even the most severe cases of CTS. Finally, that Preop and Postop EMG examinations were conducted by the same neurologist and in the same setting ensured no introduction of confounding factors attributable to differing opinions of different medical professionals or to environmental effects.

The present study had certain limitations, including that patients with idiopathic and secondary CTS were included regardless of their age or sex. Having reviewed the literature since 1947, when Phalen first popularised the diagnosis and treatment of this disease, we determined that no previous reports on the mini-open incision technique described in this publication have been reported in the English language literature.

Conclusions

Our study demonstrated that a SV 1-cm skin incision was a cosmetically satisfying, fast, and safe approach to CTR that was not only clinically but electrophysiologically effective.

Conflicts of interest

We declare that we have no actual or potential conflict of interest with regard to the manuscript submitted and have no

financial and personal relationships with other people or organizations that could inappropriately influence our work.

References:

1. Atroshi I, Gummesson C, Johnsson R et al: Prevalence of carpal tunnel syndrome in a general population. *JAMA*, 1999; 282: 153–58
2. Huang JH, Zager EL: Mini-open carpal tunnel decompression. *Neurosurg*, 2004; 54: 397–99
3. Cokluk C, Senel A, Iyigün O et al: Open median nerve release using double mini skin incision in patients with carpal tunnel syndrome: Technique and clinical results. *Neurol Med Chir (Tokyo)*, 2003; 43: 465–67
4. Mondelli M, Giannini F, Giacchi M: Carpal tunnel syndrome incidence in a general population. *Neurology*, 2002; 58: 289–94
5. D'Arcy CA, McGee S: The rational clinical examination. Does this patient have carpal tunnel syndrome? *JAMA*, 2000; 283: 3110–17
6. Bland JD, Rudolfer SM: Clinical surveillance of carpal tunnel syndrome in two areas of the United Kingdom, 1991–2001. *J Neurol Neurosurg Psychiatry*, 2003; 74: 1674–79
7. Rosenbaum R: Carpal Tunnel Syndrome. In: Johnson RT, Griffin WJ (eds.), *Current therapy in neurologic disease*. 5th ed. USA: Mosby-Year book Inc., 1997; 374–77
8. Uchiyama S, Itsubo T, Nakamura K et al: Current concepts of carpal tunnel syndrome: pathophysiology, treatment, and evaluation. *J Orthop Sci*, 2010; 15: 1–13
9. Sekijima Y, Uchiyama S, Tojo K et al: High prevalence of wild-type trans-thyretin deposition in patients with idiopathic carpal tunnel syndrome: A common cause of carpal tunnel syndrome in the elderly. *Hum Pathol*, 2011; 42: 1785–91
10. Werner RA, Andary M: Carpal tunnel syndrome: Pathophysiology and clinical neurophysiology. *Clin Neurophysiol*, 2002; 113: 1373–81
11. Iida J, Hirabayashi H, Nakase H, Sakaki T: Carpal tunnel syndrome: Electrophysiological grading and surgical results by minimum incision open carpal tunnel release. *Neurol Med Chir (Tokyo)*, 2008; 48: 554–59
12. Rempel D, Evanoff B, Amadio PC et al: Consensus criteria for the classification of carpal tunnel syndrome in epidemiologic studies. *Am J Public Health*, 1998; 88: 1447–51
13. Cranford CS, Ho JY, Kalainov DM, Hartigan BJ: Carpal tunnel syndrome. *J Am Acad Orthop Surg*, 2007; 15: 537–48
14. Huisstede BM, Randsdorp MS, Coert JH et al: Carpal tunnel syndrome. Part II: effectiveness of surgical treatments – a systematic review. *Arch Phys Med Rehabil*, 2010; 91: 1005–24
15. Avci S, Sayli U: Carpal tunnel release using a short palmar incision and a new knife. *J Hand Surg Br*, 2000; 25: 357–60
16. Atroshi I, Larsson GU, Ornstein E et al: Outcomes of endoscopic surgery compared with open surgery for carpal tunnel syndrome among employed patients: Randomised controlled trial. *BMJ*, 2006; 332: 1473
17. Cellocco P, Rossi C, Bizzarri F et al: Mini-open blind procedure versus limited open technique for carpal tunnel release: A 30-month follow-up study. *J Hand Surg Am*, 2005; 30: 493–99
18. Isik HS, Bostanci U: Experience of Carpal Tunnel Syndrome that operated using a limited uni skin incision. *Turk Neurosurg*, 2011; 21: 177–80
19. Lee H, Jackson TA: Carpal tunnel release through a limited skin incision under direct visualization using a new instrument, the carposcope. *Plast Reconstr Surg*, 1996; 98: 313–19
20. Serra JM, Benito JR, Monner J: Carpal tunnel release with short incision. *Plast Reconstr Surg*, 1997; 99: 129–35
21. Steinberg DR: Surgical release of the carpal tunnel. *Hand Clin*, 2002; 18: 291–98
22. Fung BW, Tang CY, Fung BK: Does aging matter? The efficacy of carpal tunnel release in the elderly. *Arch Plast Surg*, 2015; 42: 278–81
23. Einhorn N, Leddy JP: Pitfalls of endoscopic carpal tunnel release. *Orthop Clin North Am*, 1996; 27: 373–80
24. Szabo R: Entrapment and compression neuropathies. In: Green D (ed.), *Green's operative hand surgery*. Churchill Livingstone, Philadelphia, 1999; 1404–47
25. Gerritsen AA, Uitdehaag BM, van Geldere D et al: Systematic review of randomized clinical trials of surgical treatment for carpal tunnel syndrome. *Br J Surg*, 2001; 88: 1285–95
26. Jablecki CK, Andary MT, So YT et al: Literature review of the usefulness of nerve conduction studies and electromyography for the evaluation of patients with carpal tunnel syndrome. *AAEM Quality Assurance Committee. Muscle Nerve*, 1993; 16: 1392–414
27. Dias JJ, Bhowal B, Wildin CJ, Thompson JR: Assessing the outcome of disorders of the hand. Is the patient evaluation measure reliable, valid, responsive and without bias? *J Bone Joint Surg Br*, 2001; 83: 235–40
28. Bland JD: Do nerve conduction studies predict the outcome of carpal tunnel decompression? *Muscle Nerve*, 2001; 24: 935–40
29. Chan L, Turner JA, Comstock BA et al: The relationship between electrodiagnostic findings and patient symptoms and function in carpal tunnel syndrome. *Arch Phys Med Rehabil*, 2007; 88: 19–24
30. Schrijver HM, Gerritsen AA, Strijers RL et al: Correlating nerve conduction studies and clinical outcome measures on carpal tunnel syndrome: Lessons from a randomized controlled trial. *J Clin Neurophysiol*, 2005; 22: 216–21
31. Ginanneschi F, Milani P, Reale F, Rossi A: Short term electrophysiological conduction change in median nerve fibres after carpal tunnel release. *Clin Neurol Neurosurg*, 2008; 110: 1025–30
32. Prick JJ, Blaauw G, Vredevelde JW, Oosterloo SJ: Results of carpal tunnel release. *Eur J Neurol*, 2003; 10: 733–36
33. El-Hajj T, Tohme R, Sawaya R: Changes in electrophysiological parameters after surgery for the carpal tunnel syndrome. *J Clin Neurophysiol*, 2010; 27: 224–26