

Cinnamaldehyde has ameliorative effects on rabbit spinal cord ischemia and reperfusion injury[☆]

Pınar Kuru Bektaşoğlu^{a,*}, Ata Türker Arıkök^b, Berrin İmge Ergüder^c, Mustafa Fevzi Sargon^d, Seda Akyıldız Altun^e, Caner Ünlüler^e, Ali Börekci^f, Hayri Kertmen^e, Erhan Çelikoğlu^f, Bora Gürer^f

^a Department of Neurosurgery, University of Health Sciences, Fatih Sultan Mehmet Education and Research Hospital, Istanbul, Turkey

^b Department of Pathology, University of Health Sciences, Dışkapı Education and Research Hospital, Ankara, Turkey

^c Department of Biochemistry, Ankara University School of Medicine, Ankara, Turkey

^d Department of Anatomy, Lokman Hekim University School of Medicine, Ankara, Turkey

^e Department of Neurosurgery, University of Health Sciences, Dışkapı Education and Research Hospital, Ankara, Turkey

^f Işinye University Faculty of Medicine, Department of Neurosurgery, Istanbul, Turkey

ARTICLE INFO

Keywords:

ATP
Adenosine triphosphate
CAT
Catalase
ELISA
Enzyme-linked immunosorbent assay
H₂O₂
Hydrogen peroxide
MDA
Malondialdehyde
MP
Methylprednisolone
MPO
Myeloperoxidase
ROM
Reactive oxygen metabolites
SCI
Spinal cord ischemia
SCIRI
Spinal cord ischemia/reperfusion injury
XO
Xanthine oxidase

1. Introduction

During thoracoabdominal aortic surgery, blood supply to the spinal cord may be interrupted, resulting in ischemia, and when blood flow is restored, reperfusion occurs. This process will be called as spinal cord ischemia/reperfusion injury (SCIRI).¹ Paraplegia is an important

unwanted event seen after this injury and dramatically affects the patients' everyday life.² Primary injury is inevitable, however secondary injury is preventable. Mitochondrial dysfunction, glutamate toxicity, oxidative stress, inflammation and apoptosis are interrelated etiopathogenesis responsible from secondary injury.^{3,4} Although there are several animal studies that have promising results,⁵⁻¹⁰ until today there

[☆] This study was presented as oral presentation at eEANS 2021 (European Association of Neurosurgical Societies annual meeting).

* **Corresponding author.** Armağan Sokak, Kaya Sitesi, A Blok, Kat:13, Daire:54, Bostancı, Kadıköy, İstanbul, Turkey.

E-mail address: drpinarkuru@gmail.com (P. Kuru Bektaşoğlu).

is no single effective clinical study could succeed in preventing SCIRI.

Cinnamaldehyde (CA), found in cinnamon, is an essential compound in traditional Chinese Medicine which has anti-inflammatory, antioxidant effects.^{11,12} Nitric oxide synthesis is inhibited and the formation of reactive oxygen metabolites (ROM) decreases due to CA, which prevents oxidation.^{11,13,14} In neurodegenerative animal models, CA was found to be neuroprotective due to its abilities to reduce oxidative stress, control neuroinflammation, enhance synaptic connections, inhibit autophagy, and decrease apoptosis.¹⁵⁻¹⁹ It has been demonstrated that giving CA before cerebral ischemia lessens ischemic damage by preventing the production of inflammatory chemicals.²⁰ Due to its anti-inflammatory characteristics, CA administration was also found to be neuroprotective in the model of irreversible cerebral ischemia.²¹ In a sub-arachnoid hemorrhage model, CA application prevented cerebral vasospasm, exerted neuroprotective effect and reduced the hippocampal injury.²² In a recent study, we also showed that CA treatment has prevented cortical and hippocampal injury in a model for traumatic brain injury via its antioxidant properties.²³ The effectiveness of CA in SCIRI has not yet been proven.

The effects of CA on oxidative stress, inflammation, and apoptosis in addition to neurological consequences are assessed in this study by contrasting them with methylprednisolone (MP), a treatment for spinal cord injury that has been shown to be effective in experiments.

2. Materials and methods

2.1. Experimental groups

Animal care and treatment were carried out in accordance with the European Communities Council Directive, 2010/63/EU, which was adopted on September 22, 2010. The Committee of Animal Ethics at Saki Yenilli Laboratory Animals Facility (dated 10/03/2019) was acquired. 40 adult male New Zealand white rabbits, weighing between 2800 and 3750 g, were allocated into the following 5 groups, each including 8 rabbits.

These were the groups:

Group 1: Control group (n = 8), laparotomy was used as the only procedure, and the rabbits did not have their aortas cross-clamped. After surgery, samples of non-ischemic spinal cord were taken without any further medical intervention.

Group 2: Ischemia group (n = 8), the spinal cords of the rabbits briefly suffered from ischemia (SCI). After the occlusion clamp evacuation, no medication was applied. The animals underwent laminectomy after that, and samples of the spinal cord were removed 24 h after the ischemia.

Group 3: Vehicle group (n = 8), the rabbits had temporary global SCI. After removing the occlusion clamp, 2 cc 0.9 % NaCl was immediately administered intraperitoneally. The animals underwent laminectomy after that, and samples of the spinal cord were removed 24 h after the ischemia.

Group 4: MP group (n = 8), The rabbits were given the same care as those in group 2, but following the occlusion clamp evacuation, they were given a single intraperitoneal dosage of 30 mg/kg of MP (Prednol, Mustafa Nevzat, Turkey). This MP dosage was selected based on prior research.^{5,6,8,9,24,25}

Group 5: CA group (n = 8), The rabbits were given the same care as those in group 2, but following the occlusion clamp evacuation, they were given a 100 mg/kg of CA (Shandong Sigmachemical Co., Ltd, China). This CA dosage was selected based on prior research.²⁶

2.2. Anesthesia and surgical procedures

The rabbits had unrestricted access to food and drink and they were kept at the optimal room temperature (18–21 °C), with the right amount of moisture, and with a 12-h light/12-h dark cycle. They were given an

intramuscular dose of 5 mg/kg of xylazine (Rompun, Bayer, Türkiye) and 70 mg/kg of ketamine (Ketalar, Parke Davis Eczacıbaşı, Türkiye) to anesthetize. Using a warming pad, body temperatures were kept at 37 °C, and anal temperatures were recorded (Digital Fever thermometer, Becton Dickinson, NJ, USA). The SCIRI procedure was followed as previously mentioned.⁶ From the left renal artery's proximal bifurcation to its distal bifurcation, the aorta was cross-clamped. This is a practical way to reproduce SCIRI's characteristics.^{5,6,8,27,28} All of the rabbits in the ischemia groups experienced paraplegia as a result of the appropriate injury caused by the 20-min ischemia and 24-h reperfusion durations.²⁹

Laminectomy was utilized to accurately uproot spinal cord samples from between the L2-L5 segments, which were then employed for biochemical, histological, and ultrastructural analyses. Prior to further examination, all serum and tissue test samples were kept at 80 °C. The tissue was homogenized the day of the analysis using a homogenizer (B. Braun Melsungen AG 853202, Melsungen, Germany) and physiologic saline (1/5 w/v) before being centrifuged at 1780 g for 20 min. Prior to analysis, the protein content of the clear supernatant was examined using Lowry's technique and corrected to equivalent amounts. For the biochemical analysis, serum samples from centrifuged blood's upper clear supernatant were used.

2.3. Serum and tissue caspase-3 concentration

Using ELISA kits, the concentrations of caspase-3 in the serum and tissues were determined (ELISA kit; Cusabio, Hubei, China). The manufacturer's instructions were followed for doing the ELISA. The entire procedure was previously made available.⁶ The result was given in ng/mL.

2.4. Serum and tissue myeloperoxidase (MPO) analyses

By using a competitive inhibition ELISA (Cusabio, Hubei, China), we were able to evaluate both the serum and tissue MPO activity. The entire procedure was previously made available.⁶ The outcomes were displayed in ng/mL.

2.5. Serum and tissue malondialdehyde (MDA) analyses

Thiobarbituric acid was used to measure the levels of MDA in the blood and tissues (TBA). The entire procedure was previously made available.⁶ The MDA concentrations were given in nM.

2.6. Serum and tissue catalase (CAT) analyses

Hydrogen peroxide (H₂O₂) at 240 nm was measured for its rate of absorbance decline to assess the amounts of CAT in serum and tissue.³⁰ In IU/mL, the data were displayed.

2.7. Serum xanthine oxidase (XO) analyses

The amount of generated uric acid from xanthine was quantified in order to evaluate the serum XO activity according to Prajda and Weber's method.³¹ The entire procedure was previously made available.⁶ At 37 °C and pH 7.5, one unit of activity was equal to 1 mol of uric acid produced each minute.

2.8. Histopathological evaluation

The obtained spinal cord samples were processed for histological analysis 24 h after the lesion. The comprehensive procedure was already published.⁶

2.9. Transmission electron microscopic tissue preparation and examination techniques

Techniques for tissue preparation and examination using transmission electron microscopy were presented with a thorough explanation.⁶ For each sample, 100 large, 100 medium, and 100 small myelinated axons were evaluated, graded from 0 to 3, and counted. Each group's 5 samples each received 5 scores. Thereafter, data were displayed as mean values, as demonstrated by Kaptanoğlu et al.³² The grading system was as follows: 0 for normal myelinated axon ultrastructure, 1 for myelin configuration separation, 2 for myelin configuration disruption, and 3 for myelin configuration honeycomb appearance.

2.10. Neurological evaluation

The hindlimb neurological function was assessed using the modified Tarlov scoring system to determine the rabbits' neurological state 24 h following surgery.^{5,8,25} Each rabbit received a score ranging from 0 to 5, as follows: 0 indicates no voluntary hindlimb movement, 1 indicates detectable joint movement, 2 indicates active movement but inability to sit without assistance, 3 indicates ability to sit but inability to hop, 4 indicates a faint hop, and 5 indicates full recovery of hindlimb function. The neurological assessment was carried out by a person who was blind to the experimental groups.

2.11. Statistical analysis

Researchers that were blinded carried out each experiment at random. The statistical program GraphPad Prism 8.0 was used to examine the data (GraphPad Software Inc., La Jolla, CA, USA). Test assumptions were verified prior to analysis. By examining the symmetry and unimodality of histograms, the normality of the data was verified. For comparing the several independent groups, the one-way analysis of variance with post-hoc Tukey's multiple comparison test was used (comparisons between all groups). *p*-values of 0.05 were considered significant. The results were reported as means SEM.

3. Results

3.1. Serum and tissue caspase-3 analyses

When compared to the control group, the mean serum and tissue caspase-3 concentrations in the ischemia and vehicle groups indicated a significant difference; the caspase-3 concentrations in these groups were greater (*p* < 0.001, for both comparisons). The serum and tissue caspase-3 concentrations in the MP and CA groups were considerably lower than those in the ischemia and vehicle groups (*p* < 0.001, for both comparisons). There was no discernible difference between the MP and CA

groups, proving that either type of treatment can stop apoptosis following SCIRI (Table 1).

3.2. Serum and tissue MPO analyses

When compared to the control group, the mean serum and tissue MPO activity were statistically substantially higher in the ischemia and vehicle groups (*p* < 0.05–0.001). The SCIRI raised the serum and tissue MPO activities, while treatment with MP (*p* > 0.05 for serum MPO not significant (NS); *p* < 0.001 for tissue MPO) or CA (*p* < 0.05 for serum MPO; *p* < 0.001 for tissue MPO) significantly lowered the MPO activities in comparison to the ischemia and vehicle groups. The serum and tissue MPO activity between the MP and CA groups showed no discernible changes (Table 1). In order to demonstrate the improvement in inflammatory reaction observed after SCIRI, elevated activities of the MPO, a marker of neutrophil migration to wounded tissue, were decreased with CA and MP treatment.

3.3. Serum and tissue MDA analyses

When compared to the control group, the mean serum and tissue MDA levels of the ischemia and vehicle groups were statistically significantly higher (*p* < 0.001 for both comparisons), demonstrating SCIRI-related damage. The comparison of the ischemia and vehicle groups with the MP (*p* < 0.001 for serum; *p* < 0.01 for tissue MDA) or CA (*p* < 0.001 for serum and tissue MDA) groups revealed a significant reduction in MDA levels for both medications. Between the MP and CA groups, no statistically significant difference was discovered (Table 1). Consequently, lipid peroxidation in SCIRI is inhibited by both CA and MP.

3.4. Serum and tissue CAT analyses

The mean blood and tissue CAT levels of the ischemia and vehicle groups were significantly different from those of the control group (*p* < 0.001, for both comparisons), indicating that these levels dropped following SCIRI. Without significant differences between the MP and CA groups, serum and tissue CAT levels were considerably elevated in the MP and CA groups when compared to the ischemia and vehicle group (*p* < 0.001, for both comparisons) (Table 1). The CAT levels dropped as a result of the oxidative stress observed after SCIRI, while CA and MP demonstrated an antioxidant effect by raising the CAT levels.

3.5. Serum XO analyses

The serum XO activity was statistically significantly higher in the ischemia and vehicle groups when compared to the control group (*p* < 0.001, for both comparisons), whereas it was statistically significantly lower in the MP and CA groups when compared to the ischemia and

Table 1
Biochemical outcomes in the test groups.

Variables	Control	Ischemia	Vehicle	MP	CA	<i>p</i> -value
Serum Caspase-3 (ng/ml)	215.3 ± 31.3 ^{a,d}	421.5 ± 55.62 ^a	403.7 ± 54.81 ^{d,m,n}	205.5 ± 42.2 ^{f,k,m}	188.5 ± 30.33 ^{h,k,n}	<0.001
Tissue Caspase-3 (ng/ml)	172.5 ± 53.98 ^{a,d}	642.8 ± 153.0 ^a	626.6 ± 116.8 ^{d,m,n}	141.3 ± 75.44 ^{f,k,m}	98.17 ± 31.03 ^{h,k,n}	<0.001
Serum CAT (IU/ml)	156.1 ± 41.97 ^{a,d}	40.47 ± 11.90 ^a	54.88 ± 11.23 ^d	112.1 ± 22.62 ^{f,k,m}	106.7 ± 11.89 ^{h,k,n}	<0.001
Tissue CAT (IU/ml)	114.5 ± 1.79 ^{a,d}	27.47 ± 10.80 ^a	25.79 ± 10.92 ^d	111.5 ± 12.82 ^{f,k,m}	106.3 ± 13.43 ^{h,k,n}	<0.001
Serum MDA (nmol/g tissue)	2.57 ± 0.51 ^{a,d}	6.41 ± 1.11 ^a	6.55 ± 1.05 ^{d,m,n}	2.51 ± 0.57 ^{f,l,m}	0.53 ± 0.41 ^{l,l,n}	<0.001
Tissue MDA (nmol/g tissue)	3.73 ± 1.23 ^{a,d}	10.66 ± 2.88 ^a	10.98 ± 3.40 ^{d,n,o}	6.39 ± 1.20 ^{g,k,o}	3.32 ± 1.53 ^{j,k,n}	<0.001
Serum MPO (ng/ml)	2.39 ± 0.46 ^{b,d}	5.49 ± 2.34 ^b	5.65 ± 1.35 ^{d,p}	3.80 ± 1.37	3.39 ± 0.99 ^{j,k,p}	<0.001
Tissue MPO (ng/ml)	3.02 ± 0.78 ^{c,e}	5.09 ± 0.96 ^c	5.51 ± 1.46 ^{e,m,n}	2.47 ± 1.38 ^{f,k,m}	1.48 ± 1.32 ^{h,k,n}	<0.001
Serum XO (mIU/ml)	10.13 ± 9.20 ^{a,d}	61.25 ± 12.75 ^a	57.50 ± 12.27 ^d	6.00 ± 5.78 ^{f,k,m}	5.12 ± 4.58 ^{h,k,n}	<0.001

a: Control vs Ischemia (*p* < 0.001), b: Control vs Ischemia (*p* < 0.01), c: Control vs Ischemia (*p* < 0.05), d: Control vs Vehicle (*p* < 0.001), e: Control vs Vehicle (*p* < 0.01), f: Ischemia vs MP (*p* < 0.001), g: Ischemia vs MP (*p* < 0.01), h: Ischemia vs CA (*p* < 0.001), i: Ischemia vs CA (*p* < 0.01), j: Ischemia vs CA (*p* < 0.05), k: MP vs CA (ns), l: MP vs CA (*p* < 0.001), m: Vehicle vs MP (*p* < 0.001), n: Vehicle vs CA (*p* < 0.001), o: Vehicle vs MP (*p* < 0.01), p: Vehicle vs CA (*p* < 0.05). CAT = catalase, CA: Cinnamaldehyde, MDA = malondialdehyde, MP = methylprednisolone, MPO = myeloperoxidase, XO = Xanthine oxidase.

vehicle groups ($p < 0.001$, for both); however, no significant difference was found between the MP and CA groups. After SCIRI, the anti-inflammatory actions of CA and MP decreased the elevated serum XO activities (Table 1).

3.6. Histopathological evaluation

The control group's spinal cord had normal morphology (Fig. 1A). In the ischemia and vehicle groups, gray matter showed diffuse bleeding and congestion, while white and gray matter clearly showed severe necrosis and diffuse edema. Invasion by lymphocytes, plasma cells, and polymorphonuclear leukocytes were prevalent in the damaged areas. The ischemic groups showed cytoplasmic eosinophilia, loss of cytoplasmic elements, and neuronal pyknosis (Fig. 1B and C). The spinal cord tissue in the MP and CA groups was protected against ischemia and reperfusion damage (Fig. 1D and E). Compared to the control group, the ischemia group had significantly higher histopathology scores ($p < 0.001$, Fig. 2). Histopathology scores in the MP and CA groups were considerably lower than in the ischemia group ($p < 0.001$, for both; Fig. 2). There was no discernible difference between the MP and CA groups (Fig. 2).

In the anterior spinal cord, there were substantially fewer normal motor neurons in the ischemia group than in the control group ($p < 0.001$, Fig. 3). In comparison to the ischemia group, there were considerably more normal motor neurons in the MP and CA groups ($p < 0.001$, for both, Fig. 3). There was no discernible difference between the MP and CA groups. SCIRI appears to be prevented histopathologically by CA and MP both (Fig. 1D and E).

3.7. Ultrastructural evaluation

Transmission electron microscopy was used to assess the ultrastructural alterations. The gray and white spinal cord matter did not exhibit any ultrastructural alterations in the control group (Fig. 4A). The neurons in the gray matter appeared normal, and there were no abnormalities in the perineuronal tissues, intracellular organelles, nuclei, or membranes. The ultrastructure of all the small and medium-sized myelinated axons was healthy. Only a few of the large myelinated

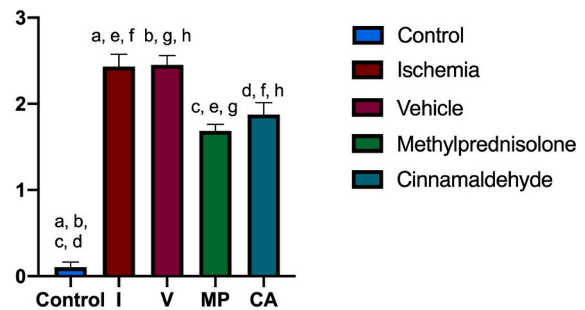


Fig. 2. Distribution of histopathology score among groups. a: Control vs Ischemia ($p < 0.001$), b: Control vs Vehicle ($p < 0.001$), c: Control vs MP ($p < 0.001$), d: Control vs CA ($p < 0.001$), e: Ischemia vs MP ($p < 0.001$), f: Ischemia vs CA ($p < 0.01$), g: Vehicle vs MP ($p < 0.001$), h: Vehicle vs CA ($p < 0.01$). CA: Cinnamaldehyde, MP = methylprednisolone.

axons were found to have mild separations; these separations may have been caused by a delay in tissue fixing.

Both the gray and white matter of the spinal cord tissues underwent severe ultrastructural pathological alterations in the ischemia and vehicle groups (Fig. 4B and C). The gray matter's ultrastructure revealed vacuoles within the cytoplasm of neurons. Additionally, these groups had perineuronal edema. The neurons' nuclei and cell membranes were healthy from an ultrastructural perspective. The myelinated axons in the white matter underwent pathological alterations. Separations in the myelin structure were readily apparent in the majority of the small-, medium-, and large-sized myelinated axons. Several of the large and medium-sized myelinated axons showed interruptions in the myelin arrangements. Small-sized myelinated axons had the least injury while large-sized myelinated axons had the worst ultrastructural damage. There was no break in the myelin structure in small myelinated axons.

In the MP group, both the gray and white matter of the spinal cord samples showed severe ultrastructural pathological alterations (Fig. 4D). Vacuoles within the cytoplasm of neurons were found in the gray matter. Perineuronal edema was additionally observed in these groups. The neurons' nucleus and cell membranes have normal

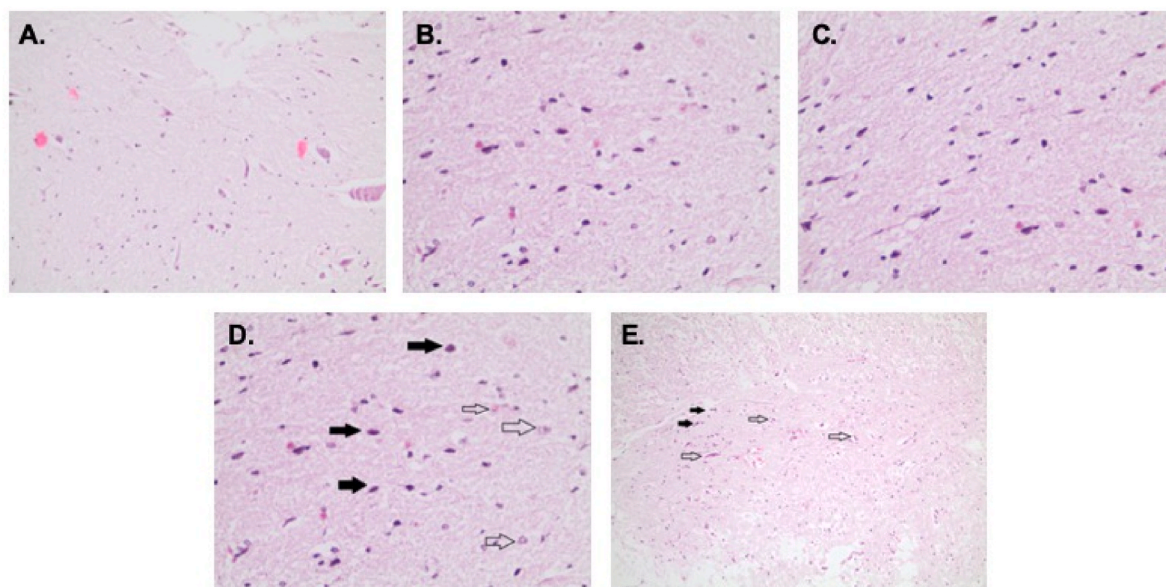


Fig. 1. 5-µm spinal cord tissue sections from each study group were photographed under a microscope. Hematoxylin-eosin stained images are displayed with a 10 objective (A) The spinal cord parenchyma in the control group is normal (B–C) Ischemia and vehicle groups, displaying deteriorated neurons on the edematous surface (D) Methylprednisolone group, displaying normal neurons (hollow arrows) and less degenerated neurons (filled arrows) (E) The Cinnamaldehyde group displays more normal neurons (hollow arrows) and less degenerative neurons (filled arrows). Cinnamaldehyde pretreatment provided protection against damage to the spinal cord tissue.

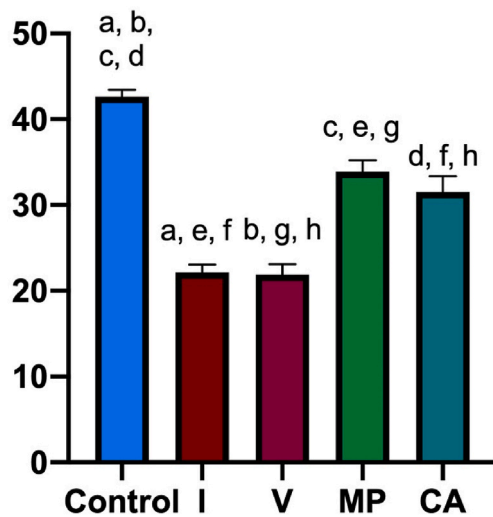


Fig. 3. Distribution of normal neuron numbers among groups. a: Control vs Ischemia ($p < 0.001$), b: Control vs Vehicle ($p < 0.001$), c: Control vs MP ($p < 0.001$), d: Control vs CA ($p < 0.001$), e: Ischemia vs MP ($p < 0.001$), f: Ischemia vs CA ($p < 0.001$), g: Vehicle vs MP ($p < 0.001$), h: Vehicle vs CA ($p < 0.001$). CA: Cinnamaldehyde, MP = methylprednisolone.

ultrastructure. The myelinated axons in the white matter showed ultrastructural pathological alterations. Most of the small, medium, and large-sized myelinated axons showed separations in the myelin structure. Moreover, some of the large and medium-sized myelinated axons showed discontinuities in the myelin arrangements. Little myelinated axons had the least severe ultrastructural pathological abnormalities,

while large myelinated axons had the most severe modifications. Moreover, no interruption in myelin structure was seen in small-sized myelinated axons.

Tissue samples from the CA group’s gray matter showed ultrastructurally healthy nuclei and membranes of neurons (Fig. 4E). Also, it was discovered that neurons’ cytoplasm included vacuoles. Perineuronal tissues showed no ultrastructural pathogenic alterations. Ultrastructurally normal small-sized myelinated axons were seen in the white matter. Some of these axons showed separations in myelin configuration. Separations in myelin structure were seen when medium- and large-sized myelinated axons were examined. In this group, there were no myelinated axons that displayed a break in myelin configuration.

Little myelinated axons in the ischemia and vehicle groups showed more apparent disruptions than in the control group ($p < 0.001$). When compared to the ischemia group, the MP and CA prevented the disruption of the small-sized myelinated axons ($p < 0.001$, for both). The small-sized myelinated axons were better protected by the MP group than by the CA group ($p < 0.001$). When compared to the control group, the ischemia group’s medium-sized myelinated axons were destroyed ($p < 0.001$). Both treatments protected the medium-sized axons from SCIRI, and there were significant differences between the ischemia group and the MP and CA groups ($p < 0.001$, for both). The ischemia group had more damaged large-sized myelinated axons than the control group did ($p < 0.001$). Both treatments preserved the medium-sized axons from SCIRI, and there were significant differences between the ischemia group and the MP and CA groups ($p < 0.001$, for both). The middle- and large-sized myelinated axons were equally protected by the MP and CA treatments (Table 2).

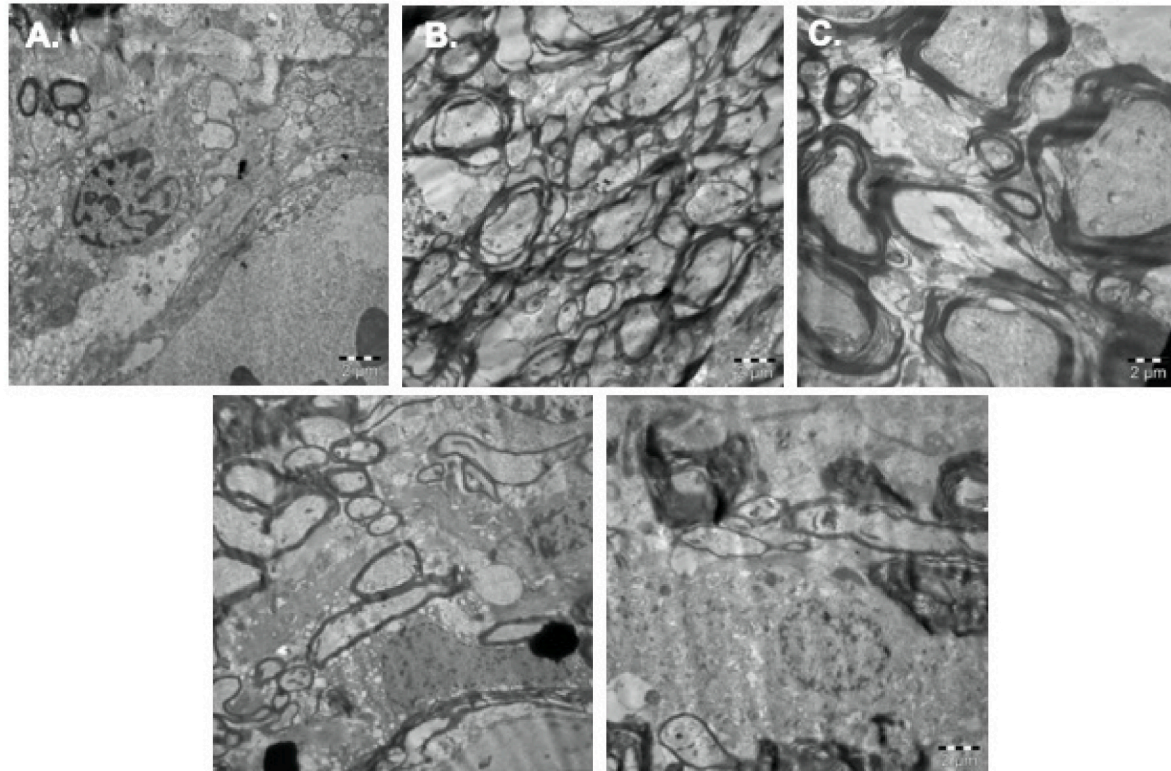


Fig. 4. Transmission electron microscope images that best represent each group (A) Control group displaying myelinated axons that are ultrastructurally normal (B–C) Ischemia and vehicle groups having separations in the myelin configurations of small, medium, and large axon sizes (black arrows) (D) Methylprednisolone group, with decreased ischemia-related myelin configuration separation in medium- and large-sized myelinated axons (white arrow) (E) Cinnamaldehyde group displays small, medium, and large myelinated axons with less separation in their myelin configurations than the ischemia groups (white arrow) (original amplification = 5000, scale bar = 2 μm , for all).

Table 2
Results from electron microscopy.

Myelinated Axon	Control	Ischemia	Vehicle	MP	CA	p-value
Small sized	0.0± 0.0 ^{a,b,d}	88.40 ± 1.14 ^{a,e}	88.40 ± 1.51 ^b f	0.0 ± 0.0 ^{e,f,g}	76.40 ± 2.40 ^{d,g}	<0.001
Middle Sized	0.0± 0.0 ^{a,b,c} d	109.8 ± 1.92 ^{a,e}	109.0 ± 2.23 ^b f	70.60 ± 2.23 ^{c,e} f,g	82.80 ± 1.64 ^{d,g}	<0.001
Large sized	5.0± 1.58 ^{a,b} c,d	124.2 ± 2.04 ^{a,e}	123.0 ± 1.0 ^{b,f}	89.0± 1.58 ^{c,e} f,g	95.20 ± 1.30 ^{d,g}	<0.001

a: Control vs Ischemia ($p < 0.001$), b: Control vs Vehicle ($p < 0.001$), c: Control vs MP ($p < 0.001$), d: Control vs CA ($p < 0.001$), e: Ischemia vs MP ($p < 0.001$), f: Vehicle vs MP ($p < 0.001$), g: MP vs CA ($p < 0.001$). CA: Cinnamaldehyde, MP = methylprednisolone.

3.8. Neurological evaluation

The mean Tarlov score was considerably lower in the ischemia and vehicle groups compared to the control group ($p < 0.001$, for both). In comparison to the ischemia group, the mean Tarlov scores in the MP and CA groups were significantly higher ($p < 0.001$, for both). In the MP and CA groups, there was no discernible difference in the Tarlov scores (Fig. 5).

4. Discussion

Spinal cord ischemia and reperfusion damage during thoracoabdominal aortic surgery may occur with an incidence of 1 %–32 % and may result in paraplegia or even death.^{33,34} Although primary injury is inevitable, secondary injury is treatable all pharmacological interventions aim to stop those interwoven cascades. Secondary injury pathways include oxidative stress, lipid peroxidation, inflammation, and apoptosis.^{3,35–37} Although numerous methods have been devised to treat spinal cord after SCIRI and protect it against thoracoabdominal aortic damage,^{38–42} there is still lack of evidence for the gold-standard management of SCIRI.

Cinnamaldehyde is a potent antioxidant, antiinflammatory compound which is found in cinnamon, and has a key role in practise of traditional

Chinese Medicine.^{11,12} CA decreases production of ROM and inhibits production of nitric oxide.^{11,13,14} Neurodegenerative animal models showed that, CA prevents neuroinflammation, suppress oxidative stress, ameliorates synaptic connectivity, suppress apoptotic cascades, prevents autophagy and highly neuroprotective.^{15–18} Administration of CA before cerebral ischemic stroke in an animal model, suppress the release of inflammatory substances.²⁰ Also in another cerebral ischemia, traumatic brain injury and cerebral vasospasm models, CA exerted neuroprotective activity via anti-inflammatory properties.^{21–23}

Apoptotic cascades activates following SCIRI and resulted in neuronal loss.^{5,6} Cessation of circulation results in ischemia and acute ATP depletion causes necrotic cell death.^{43,44} Reperfusion aggravates this apoptotic process.^{45,46} Caspase-3 is one of the main indicator of apoptotic activity,^{47,48} and previously reported as an reliable marker in SCIRI studies.^{5,8,25,48,49} CA decreases oxidative stress and stops the loss of mitochondrial membrane potential, which stops apoptosis.⁵⁰ In the present investigation, we demonstrated that both serum and spinal cord tissue caspase-3 concentrations rise after SCIRI. Treatments with CA and MP reduced the levels of caspase-3 in the spinal cord and serum, preventing apoptotic damage.

As a response to SCIRI, inflammatory cascades are activated.^{51–53} Microglial cells in the spinal cord injury emit pro-inflammatory cytokines, and inflammatory cells build up in the injured spinal cord tissue.⁵⁴ Following reperfusion injury, response of neutrophils, monocytes, and macrophages increase and deteriorate the damage.⁵⁵ Anti-inflammatory substances tested on SCIRI model and researchers obtained promising results.^{51,55,56} In numerous neuroinflammatory animal models, anti-inflammatory, and neuroprotective activity of CA has been shown.^{17,22,23,57–59} After spinal cord damage, MPO activity—a sign of neutrophil activation—increases.⁶⁰ In the current investigation, SCIRI enhanced the serum and tissue MPO activity, whereas CA and MP therapy lowered that elevated activity. This increase after SCIRI was ameliorated with CA treatment and this finding proves the anti-inflammatory activity of CA treatment in SCIRI.

Free radical formation and lipid peroxidation are also the part of tissue response following SCIRI. It has been demonstrated that increased free radical production is associated with neuronal loss following traumatic spinal cord injury.⁶¹ Lipid peroxidation takes place in lipid bilayer and marker of this process, MDA, occurs as an end product of polyunsaturated fatty acid degradation.⁶² MDA levels elevate following SCIRI.⁶³ In our investigation, the ischemic groups also had higher serum and tissue MDA levels. Treatments with CA and MP reduced MDA levels, which reduced lipid peroxidation in the spinal cord after SCIRI.

Reactive oxygen species production contributes to subsequent damage after SCIRI.⁶⁴ CAT is an antioxidant enzyme and buffers the effects of ROS and consumed due to increased oxidative stress response.^{5,8,25,27,48} CA has a potent antioxidant activity and its efficacy has been proven in a traumatic brain injury model.²³ In our investigation, serum and tissue CAT levels rose following CA and MP treatments while they dropped after SCIRI. The existence of elevated oxidative stress is indicated by the XO enzyme, which is a member of the ROS family.^{65,66} The ischemia group in the current study had elevated serum XO activity, whereas the CA and MP groups had lower levels. In light of these findings from CAT and XO activities, CA has potent antioxidant activity after SCIRI.

In the present SCIRI study, ischemia groups showed prominent hemorrhage, increased edema, and necrosis. The injured areas were filled with polymorphonuclear leukocytes, lymphocytes, and plasma cells, which are well-known inflammatory indicators. The loss of the normal motor neurons was evident in the ischemia groups. Histopathologically, the CA and MP treatments ameliorated the damage induced by SCIRI and preserved the motor neurons. In groups with ischemia, many segregations in myelinated axons of different sizes were clearly visible. The small-, middle-, and large-sized axons from SCIRI were intact after CA or MP therapy.

Also, we used the Tarlov scoring system in the current study to

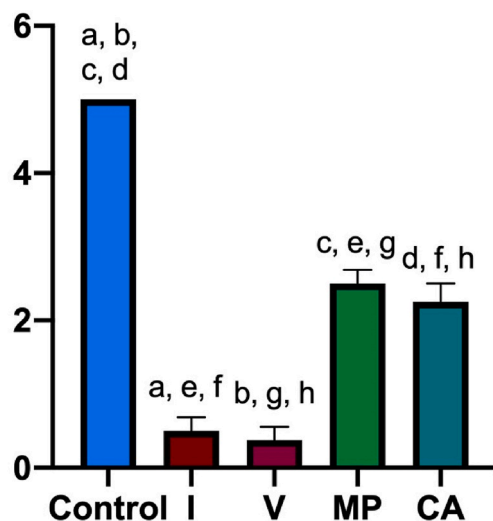


Fig. 5. Distribution of Tarlov score among groups. a: Control vs Ischemia ($p < 0.001$), b: Control vs Vehicle ($p < 0.001$), c: Control vs MP ($p < 0.001$), d: Control vs CA ($p < 0.001$), e: Ischemia vs MP ($p < 0.001$), f: Ischemia vs CA ($p < 0.001$), g: Vehicle vs MP ($p < 0.001$), h: Vehicle vs CA ($p < 0.001$). CA: Cinnamaldehyde, MP = methylprednisolone.

evaluate the functional and neurological outcomes. Paresis to some extent was seen in all rabbits. Hopefully, CA and MP treatment showed promising amelioration in the functional outcomes besides their alleviating effects on biochemical and histopathological findings.

Methylprednisolone has a historical importance in spinal cord injury as an anti-inflammatory, antioxidant, and antiapoptotic agent.^{4,67,68} Current evidence does not support its use in clinical settings.⁶⁹ In this study we preferred MP as a control groups because the literature support its efficacy in SCI animal models.^{5,8,25,27,48} Therefore, we compared efficacy of CA with MP as an active control group.

There are also some limitations for this study. Animal number per group could be higher, various dosage regimens, with different treatment timing could have been preferred. In the current study SCIRI was evaluated at 24 h of injury, which makes it harder for the clinicians to translate the data for the clinical settings. The 24 h timeframe may not capture the full scope of reperfusion injury/secondary injury. Future studies should analyze different timeframes. More detailed parameters could have been added to the study. Time dependent changes in the pathology and treatment results could give more insight about the future application for this compound in the clinical cases. In order to support the role of CA treatment in SCIRI, extended study methods are therefore required.

5. Conclusion

For the first time in the literature, the antioxidant, anti-inflammatory, anti-apoptotic, and neuroprotective effects of CA on SCIRI were demonstrated in this work. The CA can be used just after the prognosed damage to neural structures thus making the operative damage lesser. To prove that CA can be therapeutic in the SCIRI, more clinical and basic research is required.

Statement of authorship

PKB: Conception or design of the work., Data analysis and interpretation., Drafting the article., Final approval of the version to be published.

ATA: Data collection., BİE: Data collection., MFS: Data collection., SAA: Data collection., CÜ: Data collection., AB: Data collection., HK: Conception or design of the work., EÇ: Critical revision of the article.

BG: Conception or design of the work., Data collection. i Critical revision of the article., Final approval of the version to be published.

CRedit authorship contribution statement

Pınar Kuru Bektaşoğlu: Conceptualization, Data curation, Formal analysis, Methodology, Validation, Visualization, Writing - original draft, Writing - review & editing. **Ata Türker Arıkök:** Data curation, Writing - review & editing. **Berrin İmge Ergüder:** Data curation, Investigation, Methodology, Writing - review & editing. **Mustafa Fevzi Sargon:** Data curation. **Seda Akyıldız Altun:** Data curation. **Caner Ünlüler:** Data curation. **Ali Börekci:** Data curation. **Hayri Kertmen:** Conceptualization, Funding acquisition, Investigation, Methodology, Supervision. **Erhan Çelikoğlu:** Investigation, Supervision. **Bora Güner:** Conceptualization, Data curation, Funding acquisition, Investigation, Methodology, Project administration, Resources, Supervision, Writing - review & editing.

Declaration of competing interest

The authors declare that they have no known competing financial interests or personal relationships that could have appeared to influence the work reported in this paper.

References

- Fan YD, Zhu ML, Geng D, et al. The study on pathological mechanism and solution method for spinal cord ischemia reperfusion injury. *Eur Rev Med Pharmacol Sci*. 2018;22:4063–4068. <https://doi.org/10.26355/eurrev.201807.15394>.
- Conrad MF, Ye JY, Chung TK, Davison JK, Cambria RP. Spinal cord complications after thoracic aortic surgery: long-term survival and functional status varies with deficit severity. *J Vasc Surg*. 2008;48:47–53. <https://doi.org/10.1016/j.jvs.2008.02.047>.
- Marsala M, Sorokin LS, Yaksh TL. Transient spinal ischemia in rat: characterization of spinal cord blood flow, extracellular amino acid release, and concurrent histopathological damage. *J Cerebr Blood Flow Metabol*. 1994;14:604–614. <https://doi.org/10.1038/jcbfm.1994.75>.
- Kwon BK, Tetzlaff W, Grauer JN, Beiner J, Vaccaro AR. Pathophysiology and pharmacologic treatment of acute spinal cord injury. *Spine J*. 2004;4(4):451–464. <https://doi.org/10.1016/j.spinee.2003.07.007>.
- Gürer B, Kertmen H, Kasim E, et al. Neuroprotective effects of testosterone on ischemia/reperfusion injury of the rabbit spinal cord. *Injury*. 2015;46(2):240–248. <https://doi.org/10.1016/j.injury.2014.11.002>.
- Gürer B, Karakoç A, Bektaşoğlu PK, et al. Comparative effects of vitamin D and methylprednisolone against ischemia/reperfusion injury of rabbit spinal cords. *Eur J Pharmacol*. 2017;813:50–60. <https://doi.org/10.1016/j.ejphar.2017.07.028>.
- Hou J, Li H, Xue C, Ma J. Lidocaine relieves spinal cord ischemia-reperfusion injury via long non-coding RNA MIAT-mediated Notch1 downregulation. *J Biochem*. 2022 Jan 3. <https://doi.org/10.1093/jb/mvab150>. mvab150.
- Kertmen H, Gürer B, Yılmaz ER, et al. The protective effect of low-dose methotrexate on ischemia-reperfusion injury of the rabbit spinal cord. *Eur J Pharmacol*. 2013;714 (1–3):148–156. <https://doi.org/10.1016/j.ejphar.2013.05.012>.
- Kertmen H, Celikoglu E, Ozturk OC, et al. Comparative effects of methylprednisolone and tetracosactide (ACTH1–24) on ischemia/reperfusion injury of the rabbit spinal cord. *Arch Med Sci*. 2018 Oct;14(6):1459–1470. <https://doi.org/10.5114/aoms.2017.65650>.
- Zhang S, Yan Y, Wang Y, et al. Inhibition of MALTI alleviates spinal ischemia/reperfusion injury-induced neuroinflammation by modulating glial endoplasmic reticulum stress in rats. *J Inflamm Res*. 2021;14:4329–4345. <https://doi.org/10.2147/JIR.S319023>.
- Davaatseren M, Jo YJ, Hong GP, et al. Studies on the anti-oxidative function of trans-cinnamaldehyde-included β -cyclodextrin complex. *Molecules*. 2017;22(12):1868. <https://doi.org/10.3390/molecules22121868>.
- Zhao H, Xie Y, Yang Q, et al. Pharmacokinetic study of cinnamaldehyde in rats by GC-MS after oral and intravenous administration. *J Pharm Biomed Anal*. 2014;89: 150–157. <https://doi.org/10.1016/j.jpba.2013.10.044>.
- Guo X, Sun W, Huang L, et al. Effect of cinnamaldehyde on glucose metabolism and vessel function. *Med Sci Mon Int Med J Exp Clin Res*. 2017;23:3844–3853. <https://doi.org/10.12659/MSM.906027>.
- Wang F, Pu C, Zhou P, et al. Cinnamaldehyde prevents endothelial dysfunction induced by high glucose by activating Nrf2. *Cell Physiol Biochem*. 2015;36(1): 315–324. <https://doi.org/10.1159/000374074>.
- Bae WY, Choi JS, Jeong JW. The neuroprotective effects of cinnamic aldehyde in an MPTP mouse model of Parkinson's disease. *Int J Mol Sci*. 2018;19(2):551. <https://doi.org/10.3390/ijms19020551>.
- Hajinejad M, Ghadarpouri M, Dabzadeh M, Forouzanfar F, Sahab-Negah S. Natural cinnamaldehyde and its derivatives ameliorate neuroinflammatory pathways in neurodegenerative diseases. *BioMed Res Int*. 2020;2020, 1034325. <https://doi.org/10.1155/2020/1034325>.
- Ho SC, Chang KS, Chang PW. Inhibition of neuroinflammation by cinnamon and its main components. *Food Chem*. 2013;138(4):2275–2282. <https://doi.org/10.1016/j.foodchem.2012.12.020>.
- Lv C, Yuan X, Zeng HW, Liu RH, Zhang WD. Protective effect of cinnamaldehyde against glutamate-induced oxidative stress and apoptosis in PC12 cells. *Eur J Pharmacol*. 2017;815:487–494. <https://doi.org/10.1016/j.ejphar.2017.09.009>.
- Pyo JH, Jeong YK, Yeo S, et al. Neuroprotective effect of trans-cinnamaldehyde on the 6-hydroxydopamine-induced dopaminergic injury. *Biol Pharm Bull*. 2013;36(12): 1928–1935.
- Chen YF, Wang YW, Huang WS, et al. Trans-Cinnamaldehyde, an essential oil in cinnamon powder, ameliorates cerebral ischemia-induced brain injury via inhibition of neuroinflammation through attenuation of iNOS, COX-2 expression and NF- κ -B signaling pathway. *NeuroMolecular Med*. 2016;18(3):322–333. <https://doi.org/10.1007/s12017-016-8395-9>.
- Zhao J, Zhang X, Dong L, et al. Cinnamaldehyde inhibits inflammation and brain damage in a mouse model of permanent cerebral ischaemia. *Br J Pharmacol*. 2015; 172:5009–5023.
- Gürer B, Kertmen H, Kuru Bektaşoğlu P, et al. The effects of Cinnamaldehyde on early brain injury and cerebral vasospasm following experimental subarachnoid hemorrhage in rabbits. *Metab Brain Dis*. 2019;34(6):1737–1746. <https://doi.org/10.1007/s11011-019-00480-7>.
- Kuru Bektaşoğlu P, Koyuncuoğlu T, Demir D, et al. Neuroprotective effect of cinnamaldehyde on secondary brain injury after traumatic brain injury in a rat model. *World Neurosurg*. 2021;153:e392–e402. <https://doi.org/10.1016/j.wneu.2021.06.117>.
- Kahveci R, Kahveci FO, Gokce EC, et al. Effects of ganoderma lucidum polysaccharides on different pathways involved in the development of spinal cord ischemia reperfusion injury: biochemical, histopathologic, and ultrastructural analysis in a rat model. *World Neurosurg*. 2021;150:e287–e297. <https://doi.org/10.1016/j.wneu.2021.02.129>.

25. Yilmaz ER, Kertmen H, Dolgun H, et al. Effects of darbepoetin- α in spinal cord ischemia-reperfusion injury in the rabbit. *Acta Neurochir.* 2012;154(6):1037–1043. <https://doi.org/10.1007/s00701-012-1298-0>; discussion 1043-4.
26. Huang J, Wang S, Luo X, Xie Y, Shi X. Cinnamaldehyde reduction of platelet aggregation and thrombosis in rodents. *Thromb Res.* 2007;119:337–342.
27. İlhan A, Yılmaz HR, Armutcu F, Gurel A, Akyol O. The protective effect of nebiivolol on ischemia/reperfusion injury in rabbit spinal cord. *Prog Neuro-Psychopharmacol Biol Psychiatry.* 2004;28:1153–1160. <https://doi.org/10.1016/j.pnpb.2004.06.023>.
28. Lukáčová N, Halát G, Chavko M, Marsala J. Ischemia-reperfusion injury in the spinal cord of rabbits strongly enhances lipid peroxidation and modifies phospholipid profiles. *Neurochem Res.* 1996;21:869–873. <https://doi.org/10.1007/BF02532334>.
29. Zivin JA, DeGirolami U. Spinal cord infarction: a highly reproducible stroke model. *Stroke.* 1980;11:200–202. <https://doi.org/10.1161/01.str.11.2.200>.
30. Aebi H. [13] catalase in vitro. *Methods Enzymol.* 1984;105:121–126. [https://doi.org/10.1016/S0076-6879\(84\)05016-3](https://doi.org/10.1016/S0076-6879(84)05016-3).
31. Prajda N, Weber G. Malignant transformation-linked imbalance: decreased xanthine oxidase activity in hepatomas. *FEBS Lett.* 1975;59(2):245–249. [https://doi.org/10.1016/0014-5793\(75\)80385-1](https://doi.org/10.1016/0014-5793(75)80385-1).
32. Kaptanoğlu E, Palaoglu S, Surucu HS, Hayran M, Beskonakli E. Ultrastructural scoring of graded acute spinal cord injury in the rat. *J Neurosurg.* 2002;97(1 Suppl):49–56. <https://doi.org/10.3171/spi.2002.97.1.0049>.
33. Panthee N, Ono M. Spinal cord injury following thoracic and thoracoabdominal repairs. *Asian Cardiovasc Thorac Ann.* 2015;23:235–246.
34. Weidauer S, Nichtwei M, Hattingen E, Berkefeld J. Spinal cord ischemia: aetiology, clinical syndromes and imaging features. *Neuroradiology.* 2015;57:241–257.
35. Beattie MS. Inflammation and apoptosis: linked therapeutic targets in spinal cord injury. *Trends Mol Med.* 2004;10:580–583.
36. Lu J, Waite P. Advances in spinal cord regeneration. *Spine (Phila Pa. 1976);24:* 926–930, 1999.
37. Lu J, Ashwell KW, Waite P. Advances in secondary spinal cord injury: role of apoptosis. *Spine (Phila Pa. 2000);25:*1859–1866, 1976.
38. Cheung AT, Weiss SJ, McGarvey ML, et al. Interventions for reversing delayed-onset postoperative paraplegia after thoracic aortic reconstruction. *Ann Thorac Surg.* 2002;74:413–419.
39. Cheung AT, Pochettino A, McGarvey ML, et al. Strategies to manage paraplegia risk after endovascular stent repair of descending thoracic aortic aneurysms. *Ann Thorac Surg.* 2005;80:1280–1288.
40. Robertson CS, Foltz R, Grossman RG, Goodman JC. Protection against experimental ischemic spinal cord injury. *J Neurosurg.* 1986;64:633–642.
41. Svensson LG, Von Ritter CM, Groeneveld HT, et al. Cross-clamping of the thoracic aorta. Influence of aortic shunts, laminectomy, papaverine, calcium channel blocker, allopurinol, and superoxide dismutase on spinal cord blood flow and paraplegia in baboons. *Ann Surg.* 1986;204:38–47.
42. Wan IY, Angelini GD, Bryan AJ, Ryder I, Underwood MJ. Prevention of spinal cord ischemia during descending thoracic and thoracoabdominal aortic surgery. *Eur J Cardiothorac Surg.* 2001;19:203–213.
43. Hayashi T, Sakurai M, Abe K, Sadahiro M, Tabayashi K, Itoyama Y. Apoptosis of motor neurons with induction of caspases in the spinal cord after ischemia. *Stroke.* 1998;29(5):1007–1012. <https://doi.org/10.1161/01.str.29.5.1007>; discussion 1013.
44. Sakurai M, Nagata T, Abe K, Horinouchi T, Itoyama Y, Tabayashi K. Survival and death-promoting events after transient spinal cord ischemia in rabbits: induction of Akt and caspase3 in motor neurons. *J Thorac Cardiovasc Surg.* 2003;125(2):370–377. <https://doi.org/10.1067/mtc.2003.112>.
45. Hearse DJ, Bolli R. Reperfusion induced injury: manifestations, mechanisms, and clinical relevance. *Cardiovasc Res.* 1992;26(2):101–108. <https://doi.org/10.1093/cvr/26.2.101>.
46. Lou J, Lenke LG, Ludwig FJ, O'Brien MF. Apoptosis as a mechanism of neuronal cell death following acute experimental spinal cord injury. *Spinal Cord.* 1998;36(10):683–690. <https://doi.org/10.1038/sj.sc.3100632>.
47. Keane RW, Kraydieh S, Lotocki G, et al. Apoptotic and antiapoptotic mechanisms after traumatic brain injury. *J Cerebr Blood Flow Metabol.* 2001;21(10):1189–1198. <https://doi.org/10.1097/00004647-200110000-00007>.
48. Kobeissy FH, Ottens AK, Zhang Z, et al. Novel differential neuroproteomics analysis of traumatic brain injury in rats. *Mol Cell Proteomics.* 2006;5(10):1887–1898. <https://doi.org/10.1074/mcp.M600157-MCP200>.
49. Gokce EC, Kahveci R, Atanur OM, et al. Neuroprotective effects of Ganoderma lucidum polysaccharides against traumatic spinal cord injury in rats. *Injury.* 2015;46(11):2146–2155. <https://doi.org/10.1016/j.injury.2015.08.017>.
50. Solaroglu I, Kaptanoğlu E, Okutan O, Beskonakli E, Attar A, Kilinc K. Magnesium sulfate treatment decreases caspase-3 activity after experimental spinal cord injury in rats. *Surg Neurol.* 2005;64:S17–S21. <https://doi.org/10.1016/j.surneu.2005.07.058>.
51. Lv C, Yuan X, Zeng HW, Liu RH, Zhang WD. Protective effect of cinnamaldehyde against glutamate-induced oxidative stress and apoptosis in PC12 cells. *Eur J Pharmacol.* 2017;815:487–494. <https://doi.org/10.1016/j.ejphar.2017.09.009>.
52. Fan L, Wang K, Shi Z, Die J, Wang C, Dang X. Tetramethylpyrazine protects spinal cord and reduces inflammation in a rat model of spinal cord ischemia-reperfusion injury. *J Vasc Surg.* 2011;54(1):192–200. <https://doi.org/10.1016/j.jvs.2010.12.030>.
53. Hasturk A, Atalay B, Calisaneler T, Ozdemir O, Oruckaptan H, Altinors N. Analysis of serum pro-inflammatory cytokine levels after rat spinal cord ischemia/reperfusion injury and correlation with tissue damage. *Turk. Neurosurg.* 2009;19:353–359.
54. Zhu P, Li JX, Fujino M, Zhuang J, Li XK. Development and treatments of inflammatory cells and cytokines in spinal cord ischemia-reperfusion injury. *Mediat Inflamm.* 2013;2013, 701970. <https://doi.org/10.1155/2013/701970>.
55. Li M, Ona VO, Chen M, et al. Functional role and therapeutic implications of neuronal caspase-1 and -3 in a mouse model of traumatic spinal cord injury. *Neuroscience.* 2000;99:333–342. [https://doi.org/10.1016/S0306-4522\(00\)00173-1](https://doi.org/10.1016/S0306-4522(00)00173-1).
56. Reece TB, Okonkwo DO, Ellman PI, et al. The evolution of ischemic spinal cord injury in function, cytoarchitecture, and inflammation and the effects of adenosine A2A receptor activation. *J Thorac Cardiovasc Surg.* 2004;128(6):925–932. <https://doi.org/10.1016/j.jtcvs.2004.08.019>.
57. Cassada DC, Gangemi JJ, Rieger JM, et al. Systemic adenosine A2A agonist ameliorates ischemic reperfusion injury in the rabbit spinal cord. *Ann Thorac Surg.* 2001;72(4):1245–1250. [https://doi.org/10.1016/S0003-4975\(01\)03057-0](https://doi.org/10.1016/S0003-4975(01)03057-0).
58. Fu Y, Yang P, Zhao Y, et al. trans-Cinnamaldehyde inhibits microglial activation and improves neuronal survival against neuroinflammation in BV2 microglial cells with lipopolysaccharide stimulation. *Evid Based Complement Alternat Med.* 2017;2017, 4730878. <https://doi.org/10.1155/2017/4730878>.
59. Shi Y, Liang XC, Zhang H, et al. Combination of quercetin, cinnamaldehyde and hirudin protects rat dorsal root ganglion neurons against high glucose-induced injury through Nrf-2/HO-1 activation and NF- κ B inhibition. *Chin J Integr Med.* 2017;23(9):663–671. <https://doi.org/10.1007/s11655-017-2405-0>.
60. Yang D, Liang XC, Shi Y, et al. Anti-oxidative and anti-inflammatory effects of cinnamaldehyde on protecting high glucose-induced damage in cultured dorsal root ganglion neurons of rats. *Chin J Integr Med.* 2016;22(1):19–27. <https://doi.org/10.1007/s11655-015-2103-8>.
61. Taoka Y, Okajima K, Uchiba M, et al. Role of neutrophils in spinal cord injury in the rat. *Neuroscience.* 1997;79(4):1177–1182. [https://doi.org/10.1016/S0306-4522\(97\)00011-0](https://doi.org/10.1016/S0306-4522(97)00011-0).
62. Bethea JR, Dietrich WD. Targeting the host inflammatory response in traumatic spinal cord injury. *Curr Opin Neurol.* 2002;15(3):355–360. <https://doi.org/10.1097/00019052-200206000-00021>.
63. Pandey KB, Rizvi SI. Markers of oxidative stress in erythrocytes and plasma during aging in humans. *Oxid Med Cell Longev.* 2010;3(1):2–12. <https://doi.org/10.4161/oxim.3.1.10476>.
64. Christie SD, Comeau B, Myers T, Sadi D, Purdy M, Mendez I. Duration of lipid peroxidation after acute spinal cord injury in rats and the effect of methylprednisolone. *Neurosurg Focus.* 2008;25(5):E5. <https://doi.org/10.3171/FOC.2008.25.11.E5>.
65. Chan PH. Role of oxidants in ischemic brain damage. *Stroke.* 1996;27(6):1124–1129. <https://doi.org/10.1161/01.str.27.6.1124>.
66. Granger DN, Kvietys PR. Reperfusion injury and reactive oxygen species: the evolution of a concept. *Redox Biol.* 2015;6:524–551. <https://doi.org/10.1016/j.redox.2015.08.020>.
67. Hille R, Nishino T. Flavoprotein structure and mechanism. 4. Xanthine oxidase and xanthine dehydrogenase. *Faseb J.* 1995;9(11):995–1003.
68. Hurlbert RJ, Hamilton MG. Methylprednisolone for acute spinal cord injury: 5-year practice reversal. *Can J Neurol Sci.* 2008;35:41–45. <https://doi.org/10.1017/S031716710000754x>.
69. Schröter A, Lustenberger RM, Obermair FJ, Thallmair M. High-dose corticosteroids after spinal cord injury reduce neural progenitor cell proliferation. *Neuroscience.* 2009;161:753–763. <https://doi.org/10.1016/j.neuroscience.2009.04.016>.