

Case Report



**Diagnosis of Alkaptonuria after Lumbar Discectomy: Case Report
and a Review of the Literature**

Habibullah DOLGUN¹, Bora GURER^{a1}, Riza Onur SARI², Erdal Resit YILMAZ¹, Zeki SEKERCİ¹

¹Diskapi Yildirim Beyazıt Training and Research Hospital, Brain Surgery, Ankara, Turkey

²Mus The State Hospital, Brain Surgery, Mus, Turkey

ABSTRACT

Alkaptonuria is a rare autosomal recessive disorder which causes degenerative changes in cartilage, intervertebral disc and other tissues. Although intervertebral disc degeneration is common in alkaptonuria; where there are only a few patients treated surgically for lumbar disc disease. Diagnosis of alkaptonuria after black colored lumbar discectomy material is a rare condition. We present a case of alkaptonuria, in which the patient was diagnosed after lumbar discectomy.

Key words: Alkaptonuria, Lumbar disc herniation, Black disc

ÖZET

Lomber Diskektomi Sonrası Konulan Alkaptonüri Tanısı: Olgu Sunumu ve Literatür Derlemesi

Alkaptonüri, kıkırdak dokuda, intervertebral disklerde ve diğer dokularda dejeneratif değişikliklere neden olan nadir bir otozomal resesif hastalıktır. Alkaptonüride intervertebral disk dejenerasyonu sık olmasına rağmen lomber disk hernisi nedeniyle opere edilen hasta sayısı oldukça azdır. Siyah renkli lomber diskektomi materyalini takiben alkaptonüri tanısı konulması çok nadir bir durumdur. Bu yazıda, lomber diskektomi sonrası alkaptonüri tanısı alan bir alkaptonüri olgusu sunulmaktadır.

Anahtar kelimeler:

Anahtar Sözcükler: Alkaptonüri, Lomber disk hernisi, Siyah disk

Alkaptonuria is a rare autosomal recessive disorder resulting from congenital deficiency of the enzyme homogentisic acid (HGA) oxidase. Due to lack of HGA oxidase enzymatic activity, HGA cannot be degraded and it accumulates in cartilage and connective tissues for years, then it forms blue-black pigmentation. Deposition of the pigment causes degenerative changes in cartilage, intervertebral disc and other tissues (1).

Although intervertebral disc degeneration is common in alkaptonuria, our review of the literature introduced only 13 patients, including ours, were treated surgically for lumbar disc herniation (2-10). Diagnosis of alkaptonuria after black colored lumbar discectomy material is a rare condition.

Here we present a case of alkaptonuria, in which the patient was diagnosed after lumbar discectomy.

CASE REPORT

A 27 year old man had a three year history of low back with left leg pain was admitted to our clinic. On his neurological examination, straight leg rising was

positive at 15 degrees on the left, plantar flexion of left foot was moderately weak and there was hypoesthesia at S1 dermatome on the left side. Lumbosacral magnetic resonance imaging (MRI) revealed a large left sided prolapse of the intervertebral disc at the L5-S1 level (Figure 1).

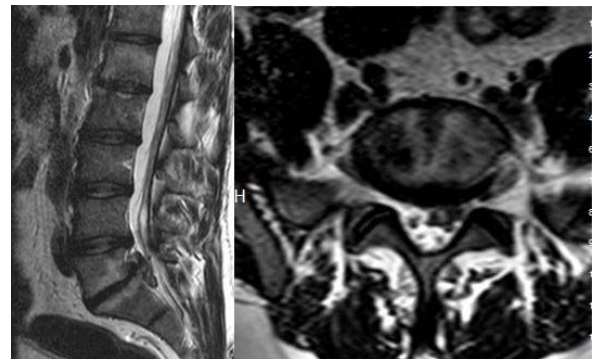


Figure 1. MRI revealed a large left sided prolapse of the intervertebral disc at the L5-S1 level.

Patient was operated in prone position under general anesthesia. There were no change of color of

^aCorresponding Adress: Dr. Bora GURER, Diskapi Yildirim Beyazıt Training and Research Hospital, Brain Surgery, Ankara, Turkey
Phone: +90 312 5962414

e-mail: boragurer@gmail.com

skin, muscle and ligaments observed. Partial hemilaminectomy and foraminotomy was performed at L5-S1 level. Good decompression of the neural structures was achieved. During L5-S1 discectomy it was realized that the extruded disc material was found degenerated and black in color (Figure 2). The histological investigation of the disc material proved that the disc was degenerated and pigmented (Figure 3).

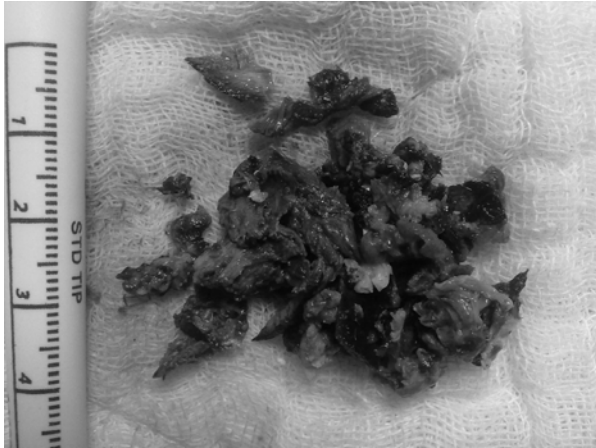


Figure 2. The discectomy material was black and degenerated.

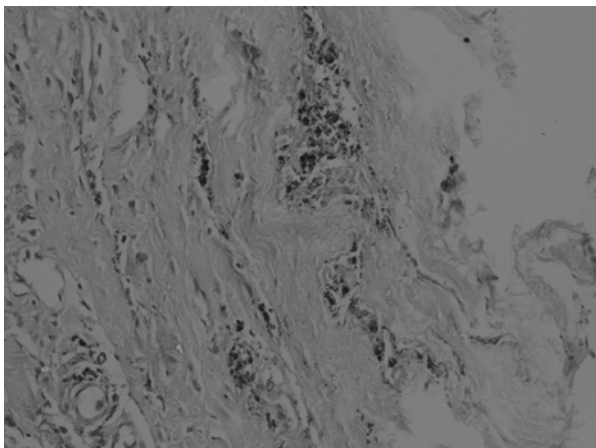


Figure 3. The histological investigation showed that the disc was degenerated and pigmented with a characteristic ochre color.

Black disc material suspected as alkaptonuria. Physical re-examination revealed no discoloration of nasal and ear cartilages in our patient. Patient's urine turned black after standing several hours in air. Qualitative measurement of the HGA level in the urine (Benedict test) was also positive. These findings confirmed the diagnosis of alkaptonuria. The cardiology, rheumatology, dermatology, ophthalmology and physical medicine and rehabilitation departments were consulted to determine the other areas of involvement. Neither other pathology nor involvement was determined at these consultations.

The patient's left leg pain disappeared completely. Phenylalanine and tyrosine-deficient diet, 100mg/day

of vitamin C and 100mg/day of diclofenac sodium were started. He was discharged 1 week after surgery and placed under long-term follow-up.

DISCUSSION

Alkaptonuria is a rare autosomal recessive disorder with a low incidence of 0.001% (1). Ochronosis is the pigmentation of connective tissues in alkaptonuric patients. Clinical manifestations of ochronosis usually appear after the age of 30. These clinical manifestations consist of blue-black pigmentation of external ear and tympanic membrane, black discoloration of the cerumen, blue, black or brown staining of the sclera and blue to black tinting of the skin in the axillary and genital regions (11).

Due to HGA oxidase enzyme deficiency, HGA accumulates in connective tissue (12). The HGA accumulation in the tissue may cause a chemical irritation, which leads to degeneration and inflammation. It is likely that HGA attaches to connective tissue and affects the macromolecular structures and the interactions between them. Some suggest that HGA leads to degeneration of oxidant products. Benzochinon acetate that forms with HGA oxidation binds to collagen diagonal bonds and impairs the connective structure. On the other hand, oxidation causes free radical formation which affects the development of tissue damage and triggers the inflammation. Finally, clinical findings regarding damage in the connective tissue (13).

Accumulation of HGA in the cartilage of joints and intervertebral discs causes degeneration of the cartilage and lead to intervertebral disc herniation mainly in the thoracic and the lumbar area (14). The disease generally begins with chronic backache and restriction in back movements. More rarely, it may begin with acute backache resulting from rupture of the annulus fibrosus (1). The first symptom was sciatica in approximately 17% of patients with alkaptonuria in one report (15) and was back pain in 60% of patients in another (16). In alkaptonuric spondylosis, degenerative changes may be seen along the whole of the spine; however the most common involvement is in the lumbar spine. The most common radiological changes of alkaptonuric spondylosis include squaring of vertebral bodies, intervertebral disc calcification, bridging syndesmophytes, and apophyseal joint involvement. When changes are advanced, the radiologic appearance is like bamboo spine (17).

Although lumbar disc rupture is common in alkaptonuria, there were only 13 patients treated surgically (Table 1). Our review of the literature revealed that most of the cases were diagnosed as alkaptonuria after surgery, when blackened nucleus pulposus was noticed during surgery. All the surgically treated alkaptonuric patients showed significant improvement after lumbar discectomy as in our case.

Table 1. Surgically treated alkaptonuric patients with lumbar disc herniation.

Author, Year	Age, Sex	Diagnosis of alkaptonuria	Level	Outcome
Fisher, 1955	32, M	After surgery	L5-S1	Significant improvement
McCollum, 1965	34, M	Before surgery	L4-5	Significant improvement
Acosta, 1967	28, M	Before surgery	L5-S1	Significant improvement
Koh, 1994	32, M	Before surgery	L5-S1	Significant improvement
Reddy, 1998	22, M	After surgery	L4-5	Significant improvement
Emel, 2000	34, M	After surgery	L4-5 and L5-S1	Significant improvement
Farzannia, 2003	43, F	After surgery	L4-5	Significant improvement
	30, F	After surgery	L4-5	Significant improvement
	28, M	After surgery	L5-S1	Significant improvement
Gurkanlar, 2006	36, M	After surgery	L5-S1	Significant improvement
	45, M	After surgery	L4-5	Significant improvement
	33, M	Before surgery	L5-S1	Significant improvement
Kalevski, 2007	33, M	Before surgery	L5-S1	Significant improvement
Present case	27, M	After surgery	L5-S1	Significant improvement

Peripheral joint arthritis develops in the later stage and generally large joints are involved. Involvement of small joints is rare (12). Renal functions may be deteriorated in patients with alkaptonuria due to accumulation of pigment in prostate. Calcification in prostate gland may cause an obstruction and renal dysfunction due to obstruction may occur (18). Cardiovascular involvement may also occur in alkaptonuric patients. Systolic murmurs were found 15-20% of the patients (19). Aortic and mitral valve involvement is usually seen in alkaptonuria. Also atherosclerotic plaques may develop in these patients, in whom myocardial infarction is the most common cause of death (20).

There is no effective treatment of alkaptonuria. In medical treatment, phenylalanine and tyrosine deficient diet as well as high dose of ascorbic acid is suggested. Non-steroid anti-inflammatory drugs may be required for arthropathy. As a conventional treatment, physical therapy and rehabilitative interventions can cause no-

table symptomatic relief (12). In addition, the use of antioxidants such as n-acetyl cysteine and vitamin E has been showed to reduce HGA accumulation in vitro (21).

Consequently, black disc material is a suspicious value for alkaptonuria in patients who undergo lumbar discectomy. These patients are candidates of other systemic involvements of alkaptonuria. After lumbar discectomy, where black disc material has been found, diagnosis of alkaptonuria is essential. These patients must be placed on long term follow-up.

Because only a few alkaptonuric patients treated surgically for lumbar disc disease have been reported, little is known about outcome. The review of the literature showed that all alkaptonuric patients, including ours, were significantly improved after lumbar discectomy. So, lumbar discectomy have been helpful in this patient group.

REFERENCES

1. Scriver CR. The hyperphenylalaninemia and alkaptonuria. In: Goldmon L, Benett JC (Editors) Cecil text book of Medicine, 21st edition. Philadelphia: WB Saunders, 2000: 1108-10.
2. Fisher RG, Williams J. Ochronosis associated with degeneration of an intervertebral disc. J Neurosurg 1955; 12: 403-6.
3. McCollum DE, Odom GL. Alkaptonuria, ochronosis, and low-back pain. A case report. J Bone Joint Surg Am 1965; 47: 1389-92.
4. Acosta C, Watts CC, Simpson CW, Patterson CE. Ochronosis and degenerative lumbar disc disease. Case report. J Neurosurg 1968; 28: 488-9.
5. Koh KB, Low EH, Ch'ng SL, Zakiah I. A case of alkaptonuria with root canal stenosis. Singapore Med J 1994; 35: 106-7.
6. Reddy DR, Prasad VS. Alkaptonuria presenting as lumbar disc prolapse: case report and review of literature. Spinal Cord 1998; 36: 523-4.
7. Emel E, Karagöz F, Aydın IH, Hacısalihoğlu S, Seyithanoğlu MH. Alkaptonuria with lumbar disc herniation: a report of two cases. Spine 2000; 25: 2141-4.
8. Farzannia A, Ghaffar S, Hadidchi S. Alkaptonuria and lumbar disc herniation. J Neurosurgery 2003; 98: 87-9.
9. Gürkanlar D, Daneyemez M, Solmaz I, Temiz C. Ochronosis and lumbar disc herniation. Acta Neurochir 2006; 148: 891-4.
10. Kalevski SK, Haritonov DG, Peev NA. Alcaptonuria with lumbar disc prolapse: case study and review of the literature. Spine J 2007; 7: 495-8.
11. Schumacher HR, Holdsworth DE. Ochronotic arthropathy 1. Clinicopathologic studies. Semin Arthritis Rheum 1977; 6: 207-46.
12. Phornphutkul C, Introne WJ, Perry MB, et al. Natural history of alkaptonuria. N Engl J Med 2002; 347: 2111-21.
13. Higashino K, Liu W, Ohkawa T, et al. A novel point mutation associated with alkaptonuria. Clin Genet 1998; 53: 228-9.
14. Kusakabe N, Tsuzuki N, Sonada M. Compression of the cervical cord due to alkaptonuric arthropathy of the atlanto-axial joint. A case report. J Bone Joint Surg 1995; 77: 274-7.

15. Cervenansky J, Sitaj S, Urbanek T. Alkaptonuria and ochronosis. J Bone Joint Surg 1959; 41: 1169-82.
16. Feild JR, Higley GB, DeSaussure RL. Ochronosis with lumbar disc. Case report. J Neurosurg 1963; 20: 348-51.
17. Balaban B, Taskaynatan M, Yasar E, Tan K, Kalyon T. Ochronotic spondyloarthropathy: spinal involvement resembling ankylosing spondylitis. Clin Rheumatol 2006; 25: 598-601.
18. Sutor DJ, Wooley SE, Krizek V. The composition of calculi from patients with alcaptonuria. Br J Urol 1970; 42: 386-8.
19. Gaines J, Pai JR. Cardiovascular ochronosis. Arch Pathol Lab Med 1987; 111: 991-4.
20. Kovacevic M, Simic O, Medved I, Lucin K, Padovan M. Ochronosis of the aortic valve and aorta. J Heart Valve Dis 2006; 15: 730-2.
21. Chindamo D, Catenaccio M, Lorenzini S, et al. N-acetylcysteine and vitamin E: an in vitro study of their effect on homogentisic acid polymerization. Clin Exp Rheumatol 2003; 21: 269.

Gönderilme Tarihi: 13.09.2011